

IVUSS BASIC ABDOMEN CASE #5

LIVER MASSES

24/03/2022

Signalment

Gypsy was an eleven-year-old female neutered Australian Cattle dog living in Cairns, Queensland. She weighed 16kg.

History

Gypsy had been previously well. In March 2022, during her annual vaccination, she was noted to have an oral mass in the gum overlying 403. She was also noted to have moderate dental disease. A full oral examination under general anaesthetic with treatment of dental disease and removal of the mass was planned.

Preanaesthetic blood tests revealed a marked increase in ALKP and a mild increase in ALT. The owner reported no clinical signs at all, Gypsy had been completely well. A full abdominal ultrasound was ordered.

Blood Tests

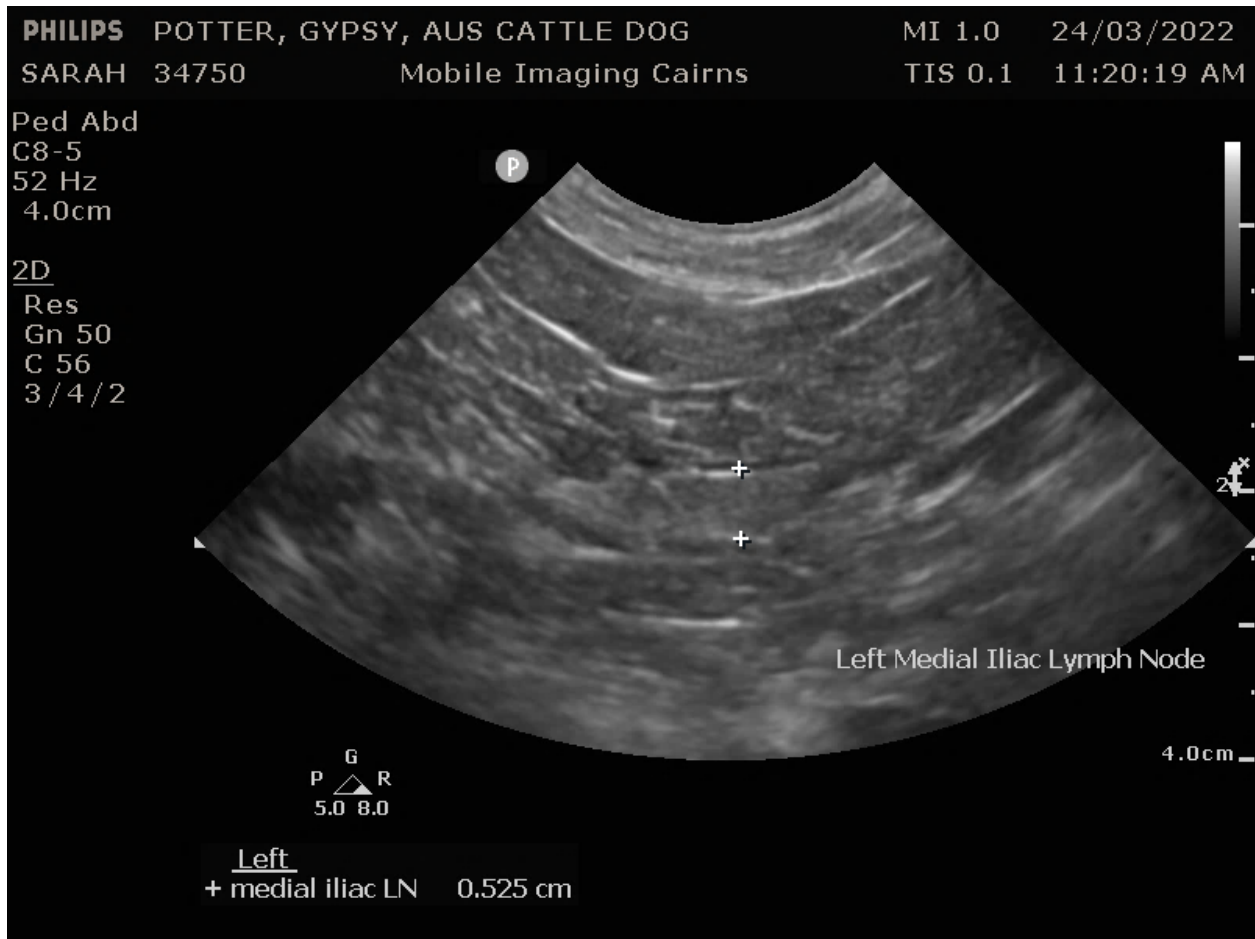
RBC	7.85	x10 ¹² /L	5.65 - 8.87
HCT	48.4	%	37.3 - 61.7
HGB	17.8	g/dL	13.1 - 20.5
MCV	61.7	fL	61.6 - 73.5
MCH	22.7	pg	21.2 - 25.9
MCHC	36.8	g/dL	32.0 - 37.9
RDW	19.8	%	13.6 - 21.7
%RETIC	0.5	%	
RETIC	40.8	K/ μ L	10.0 - 110.0
RETIC-HGB	24.4	pg	22.3 - 29.6
WBC	11.85	x10 ⁹ /L	5.05 - 16.76
%NEU	69.5	%	
%LYM	22.0	%	
%MONO	4.9	%	
%EOS	3.3	%	
%BASO	0.3	%	
NEU	8.23	x10 ⁹ /L	2.95 - 11.64
LYM	2.61	x10 ⁹ /L	1.05 - 5.10
MONO	0.58	x10 ⁹ /L	0.16 - 1.12
EOS	0.39	x10 ⁹ /L	0.06 - 1.23
BASO	0.04	x10 ⁹ /L	0.00 - 0.10
PLT	385	K/ μ L	148 - 484

MPV	13.7	fL	8.7 - 13.2	HIGH
PDW	14.1	fL	9.1 - 19.4	
PCT	0.53	%	0.14 - 0.46	HIGH
GLU	7.56	mmol/L	3.89 - 7.95	
CREA	60	μmol/L	44 - 159	
UREA	4.9	mmol/L	2.5 - 9.6	
BUN/CREA	20			
TP	80	g/L	52 - 82	
ALB	38	g/L	22 - 39	
GLOB	42	g/L	25 - 45	
ALB/GLOB	0.9			
ALT	184	U/L	10 - 125	HIGH
ALKP	1644	U/L	23 - 212	HIGH

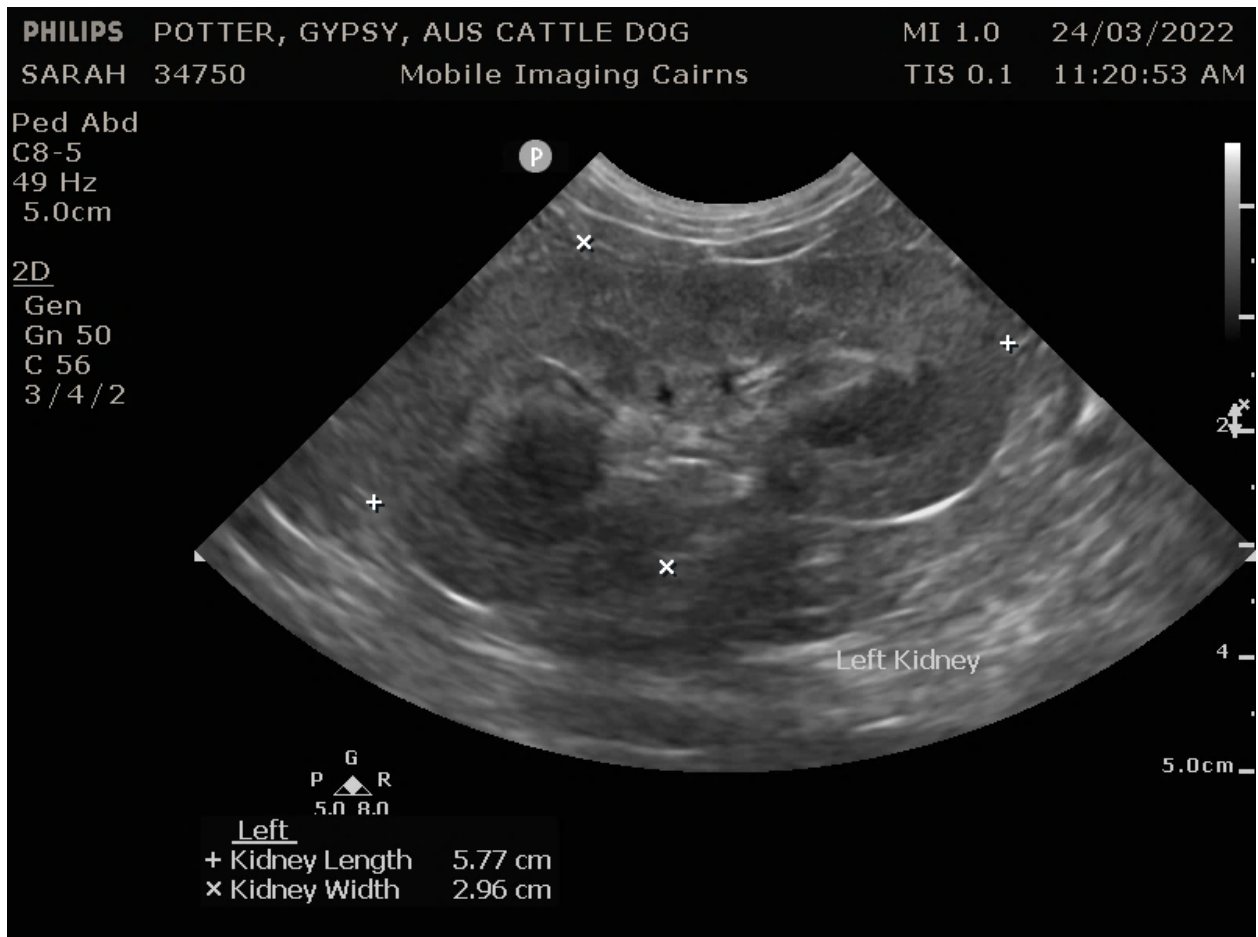
Physical exam

Gypsy was bright, alert and normally responsive. She was strong, and able to walk. Her temperature, pulse rate and breathing rate were within normal limits. There were no abnormalities detected on examination of her ears, eyes, lymph nodes, skin and coat, gait or musculoskeletal system. Thoracic auscultation and abdominal palpation were unremarkable. She had moderate dental disease and an oral mass on the buccal gingiva associated with 403.

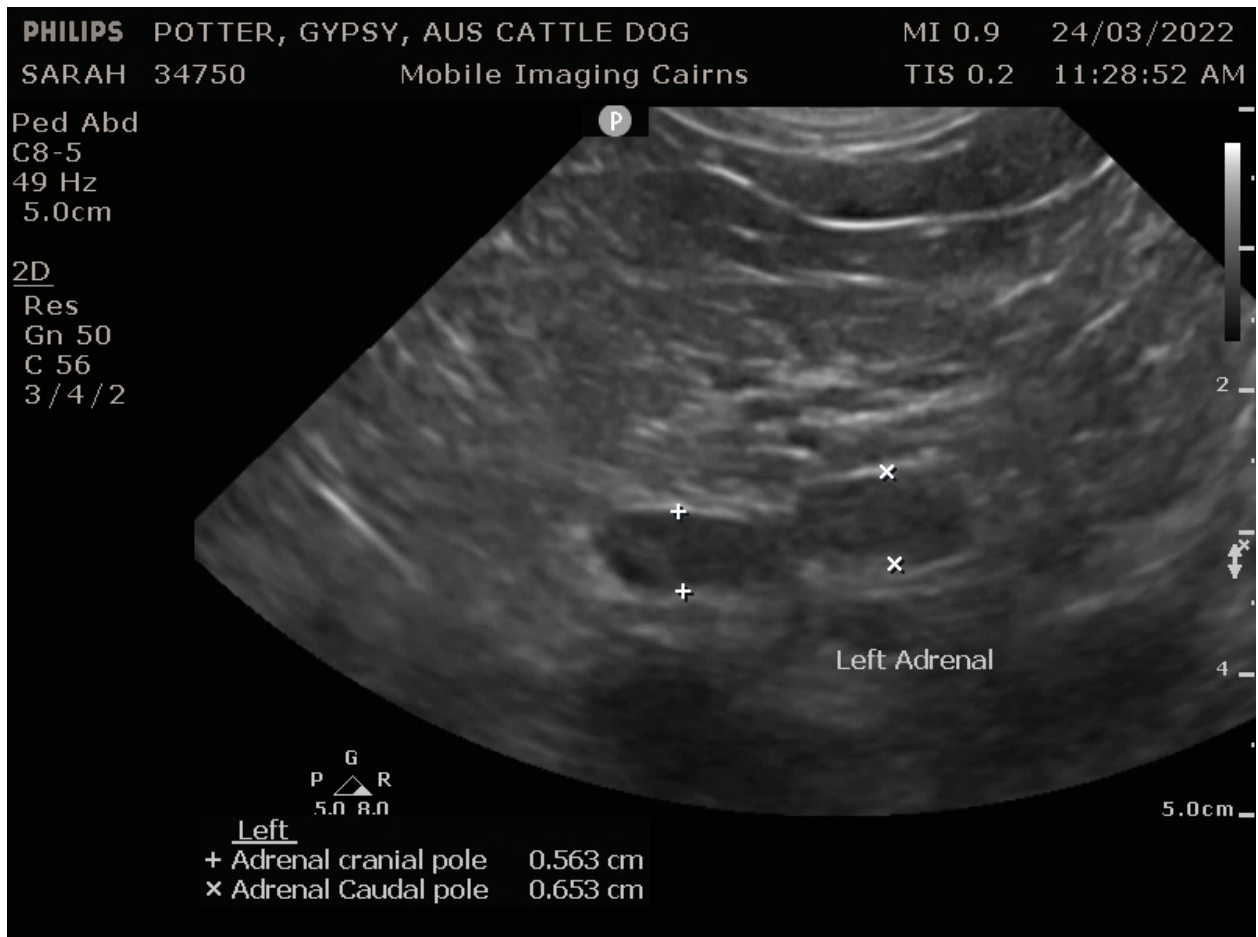
Ultrasound assessment:



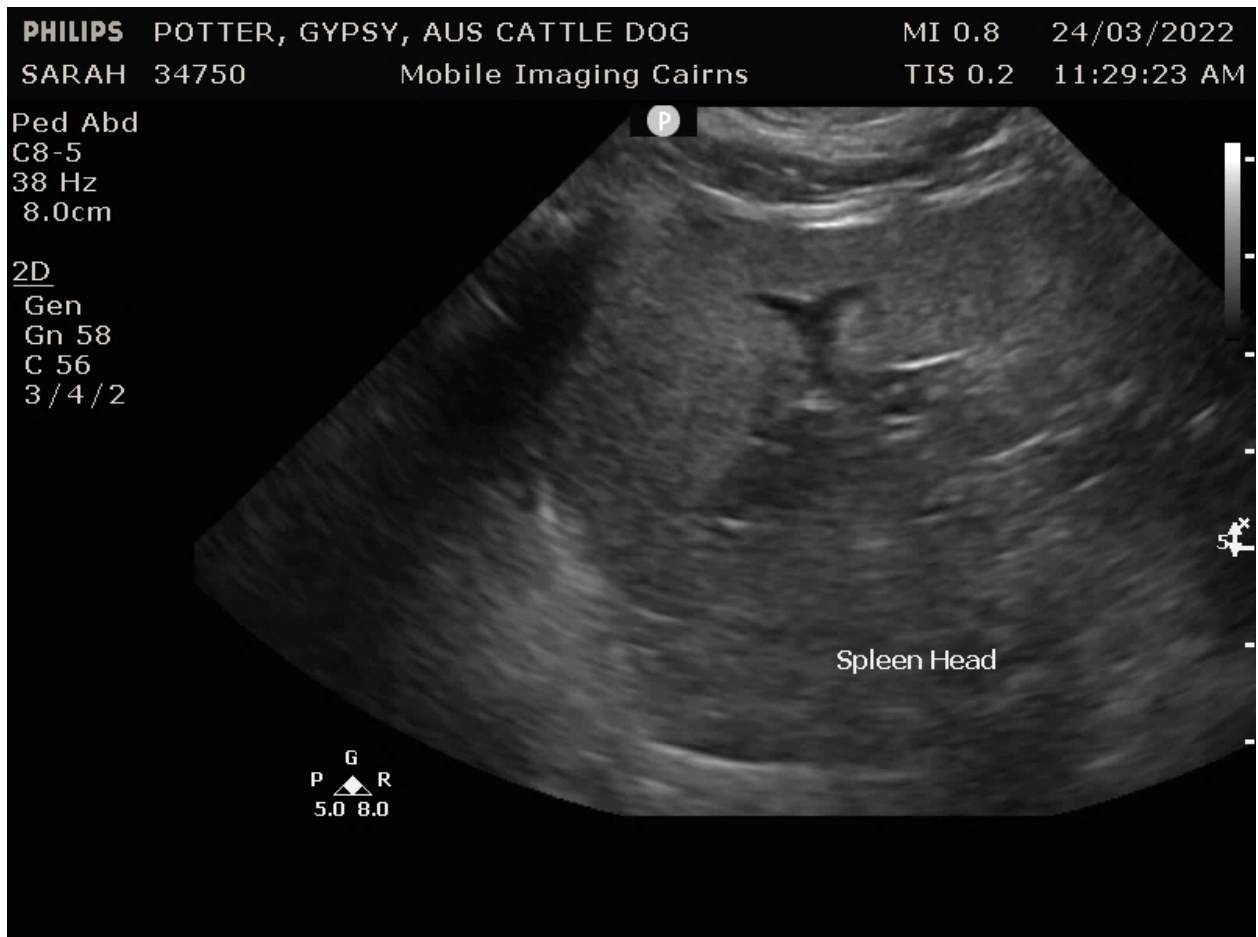1. Longitudinal view of the left medial iliac lymph node. It is 0.525cm thick. It is normal in shape, has smooth margins, it is isoechoic relative to its surrounds.



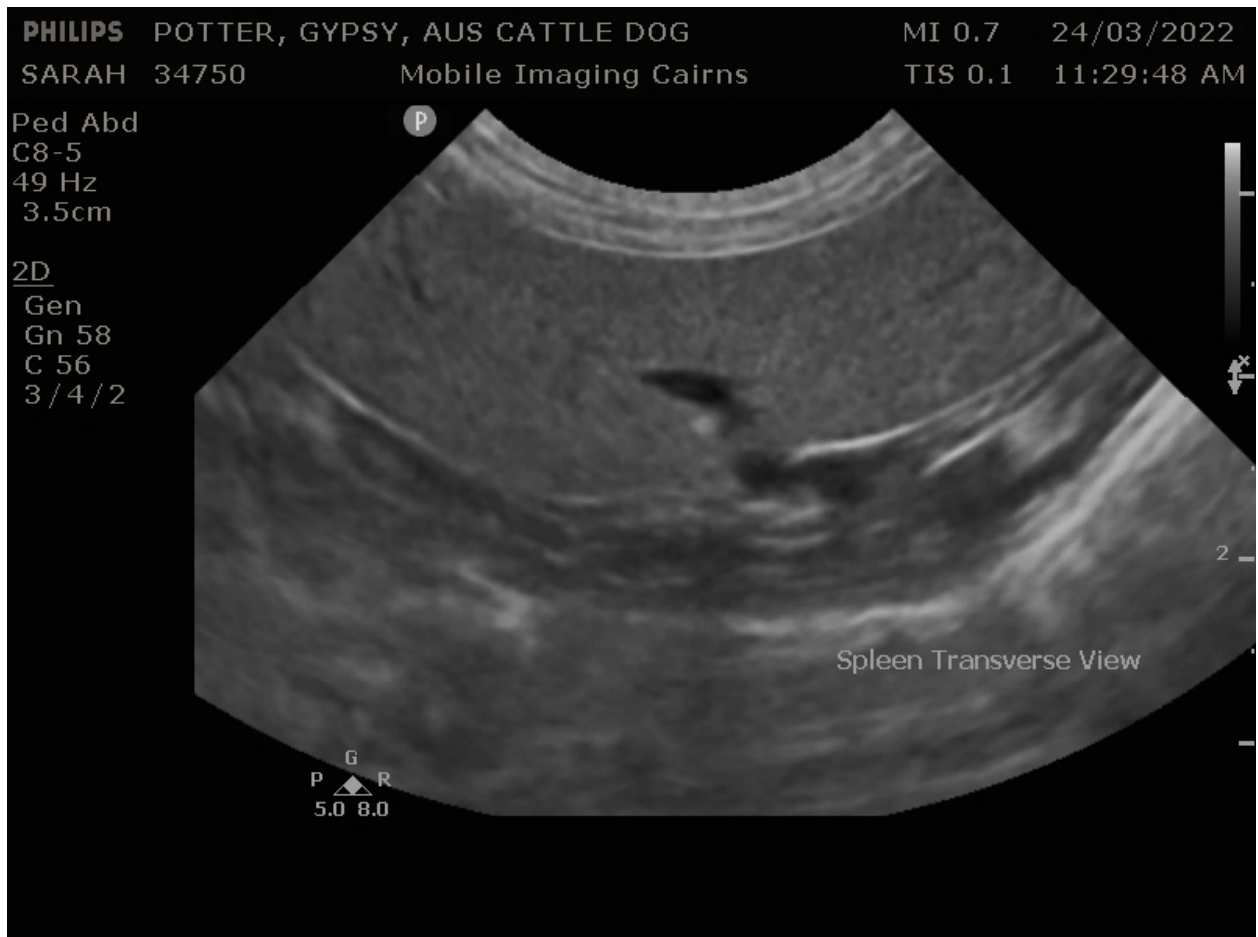
2. Left kidney dorsal view with measurement. There is good corticomedullary definition present with smooth regular margins. The length is 5.77cm and the width is 2.96cm. The kidney appears normal.



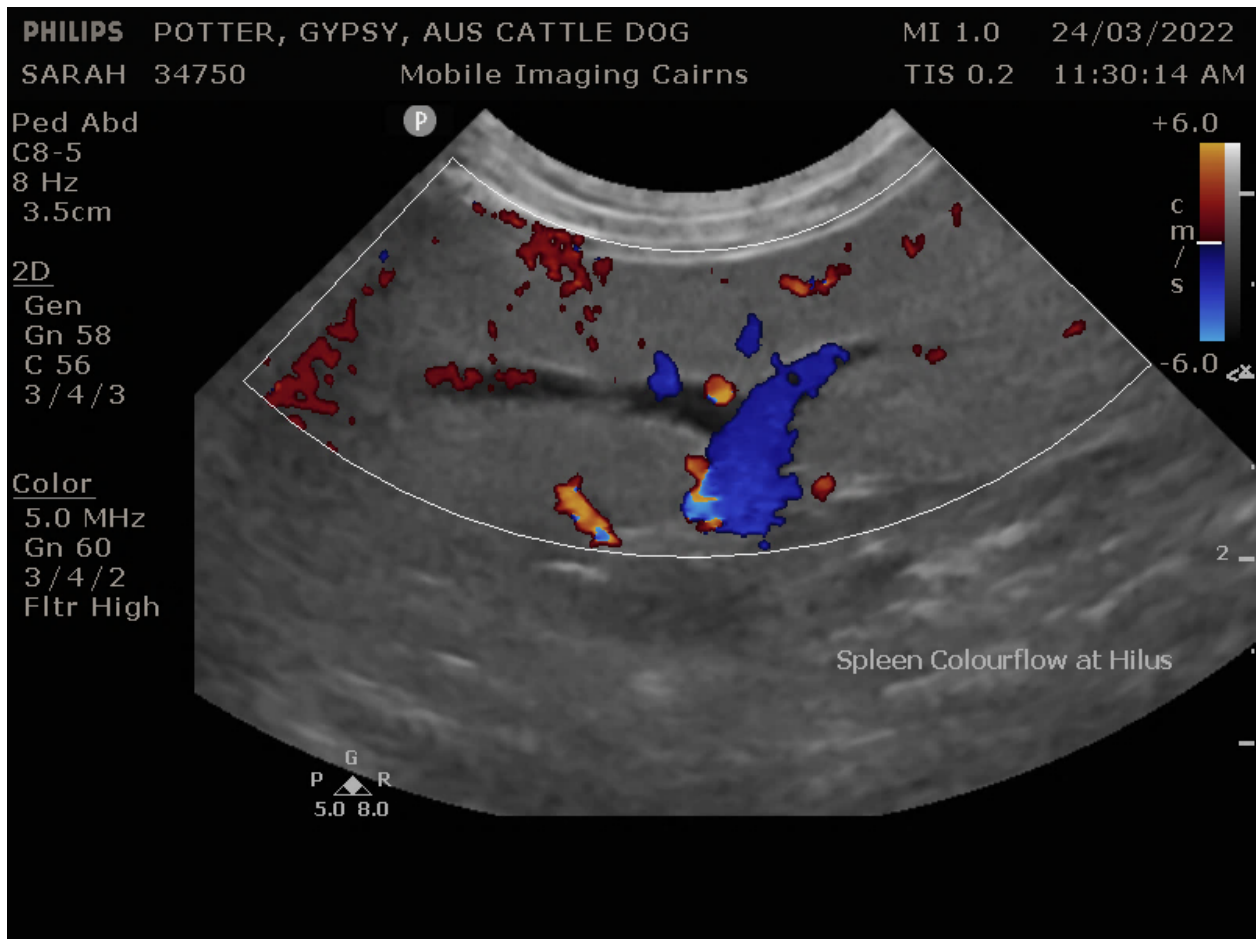
3. Left adrenal with measurements. The diameter of the cranial pole is 0.563cm and the diameter of the caudal pole is 0.653cm, this is within normal limits².



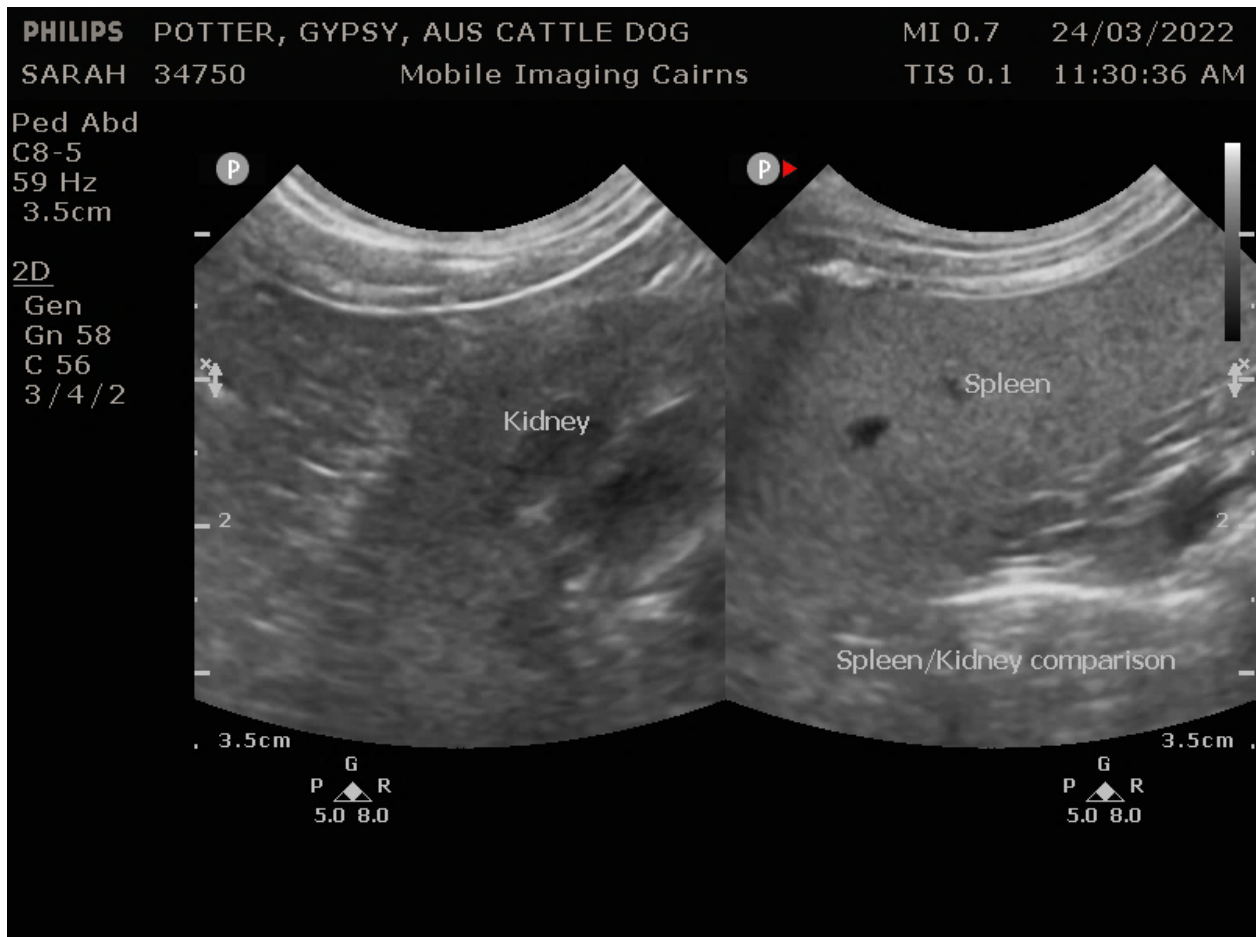
4. Transverse view of the head of the spleen. The shape is normal, the margins are smooth, the echotexture is uniform.



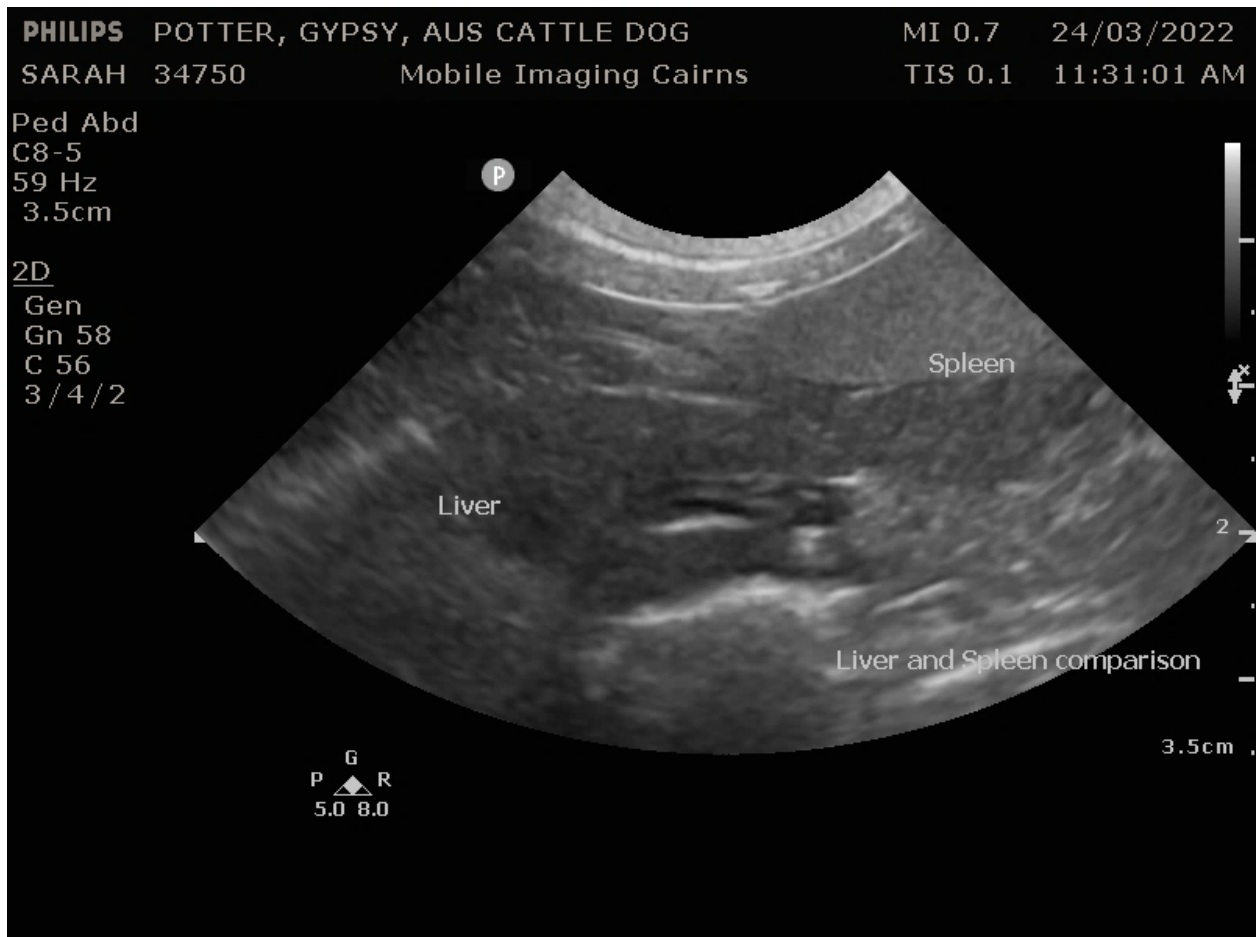
5. Transverse view of the spleen. The shape is normal, the margins are smooth, the echotexture is uniform.



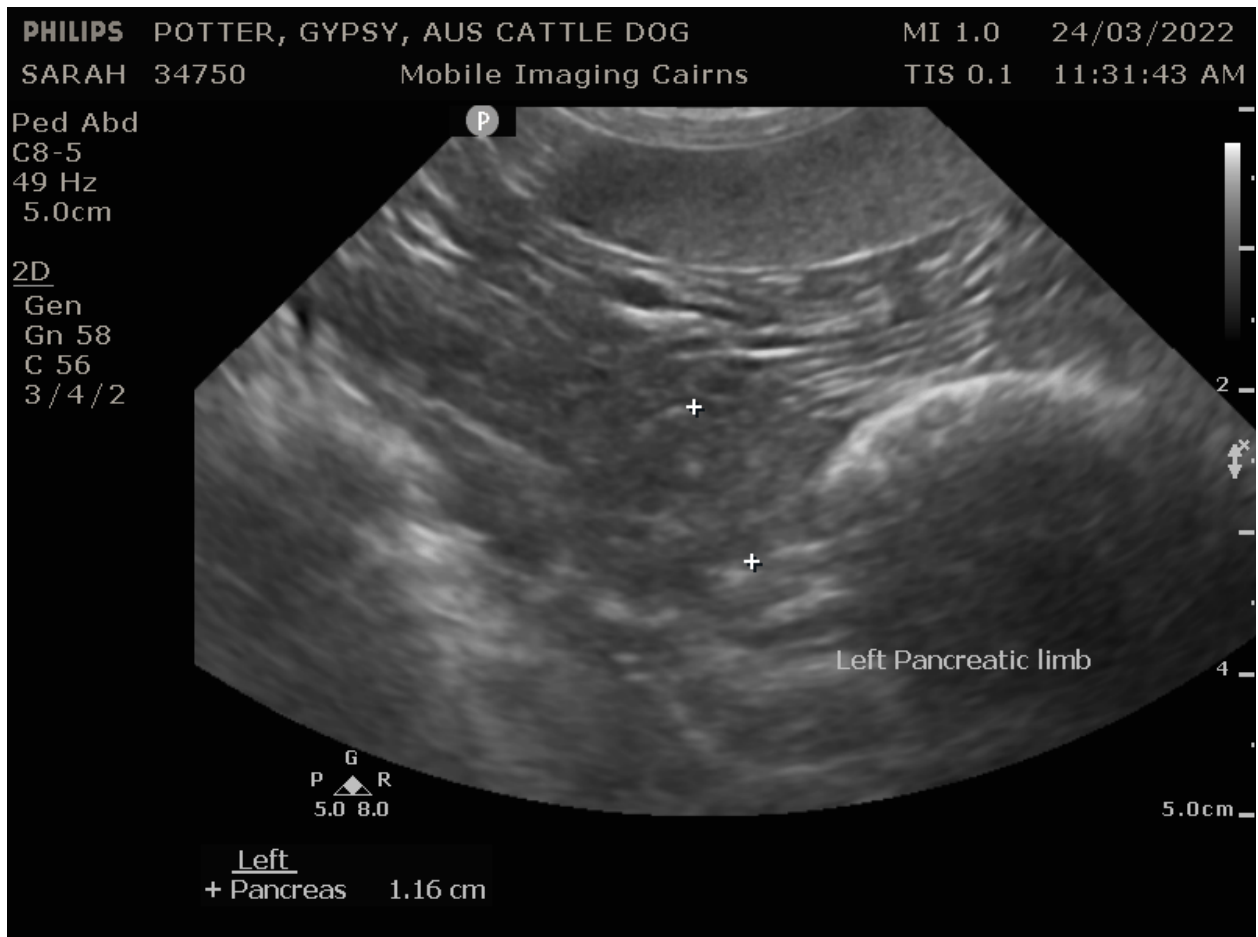
6. Spleen with the hilus vessel and colour doppler flow on hilus vessels demonstrating normal splenic blood flow.



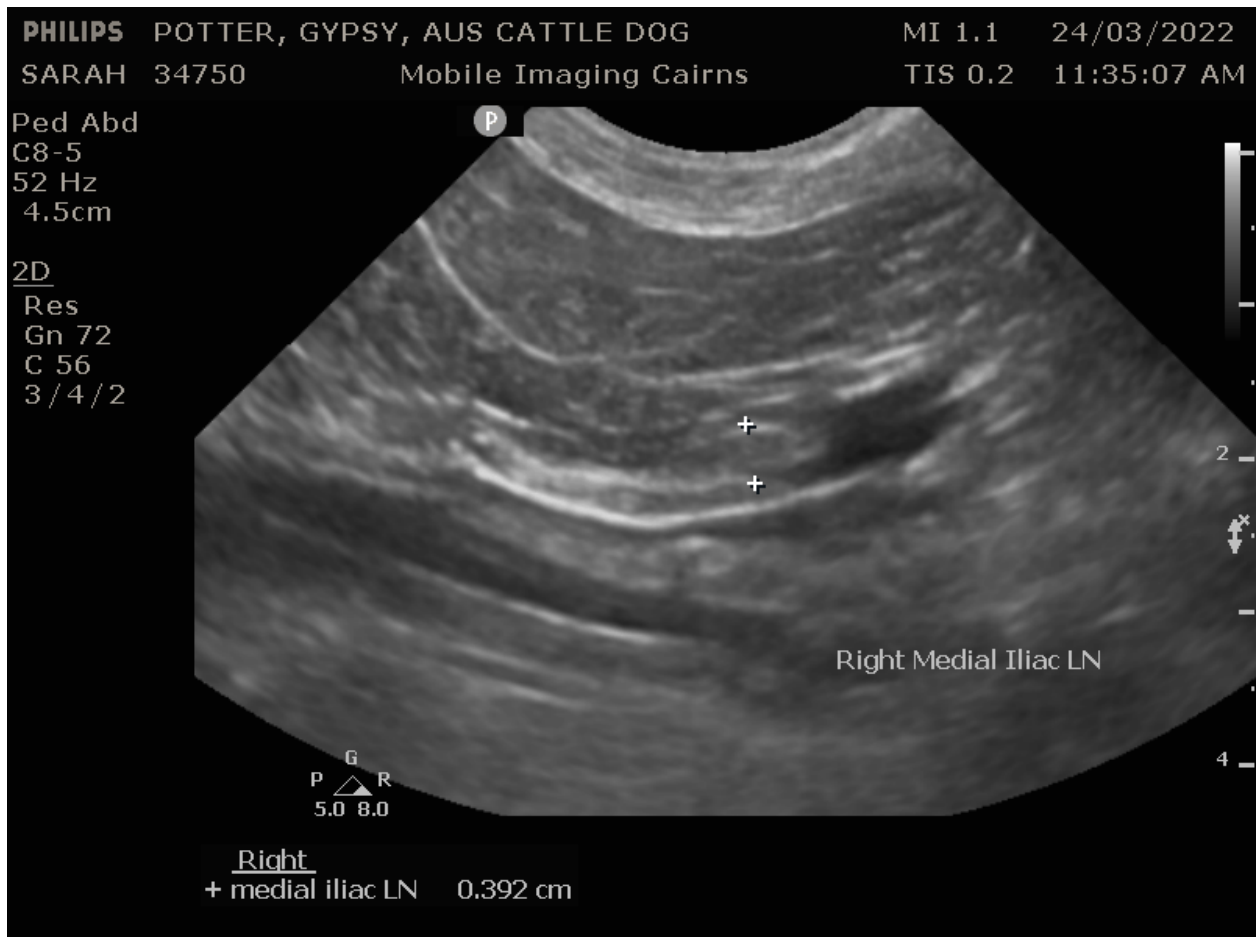
7. Left kidney/spleen comparison. At the same depth and gain settings the left renal cortex is hypoechoic relative to the spleen, which is normal.



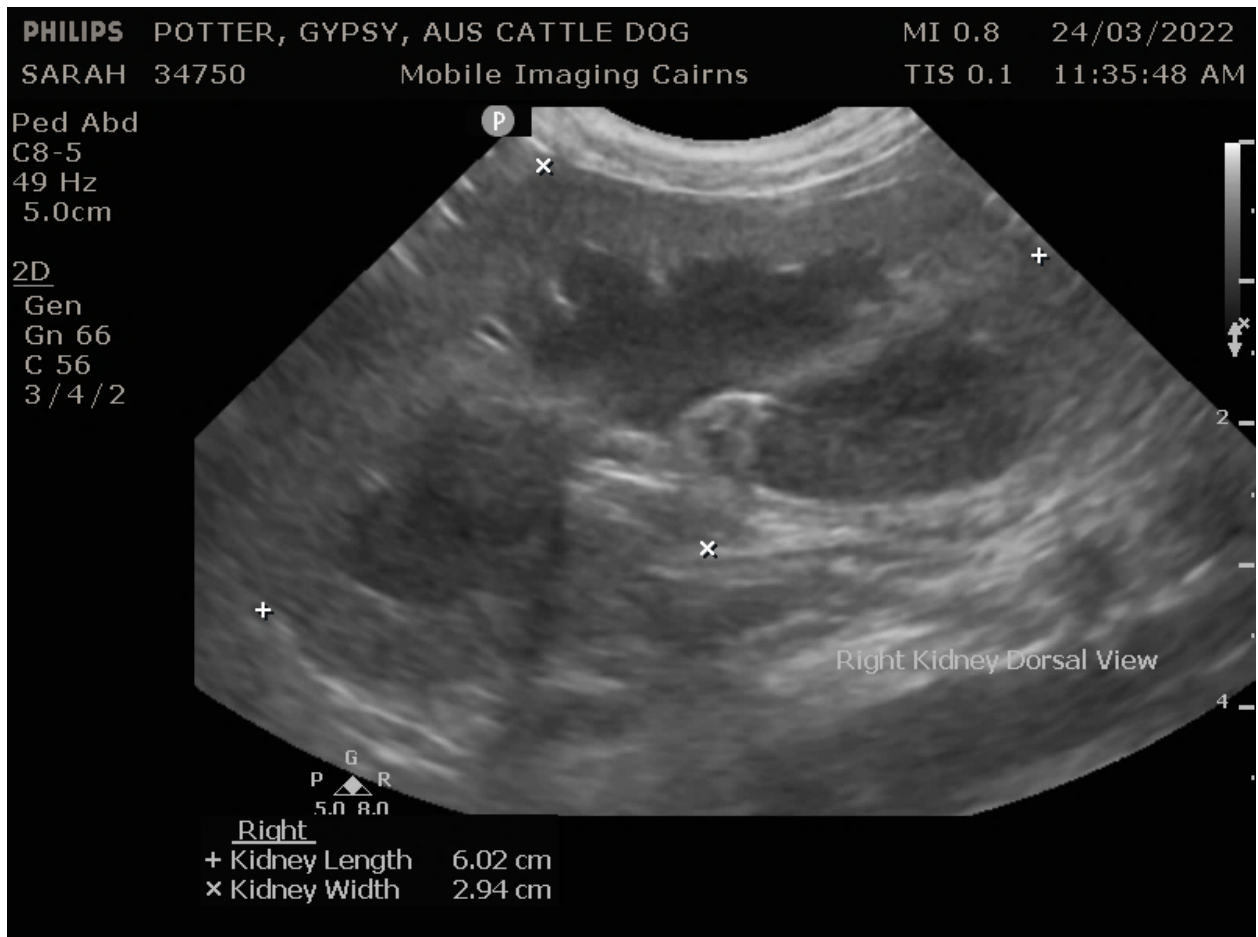8. Liver/spleen comparison. At the same depth and gain settings the liver is hypochoic relative to the spleen, which is normal.



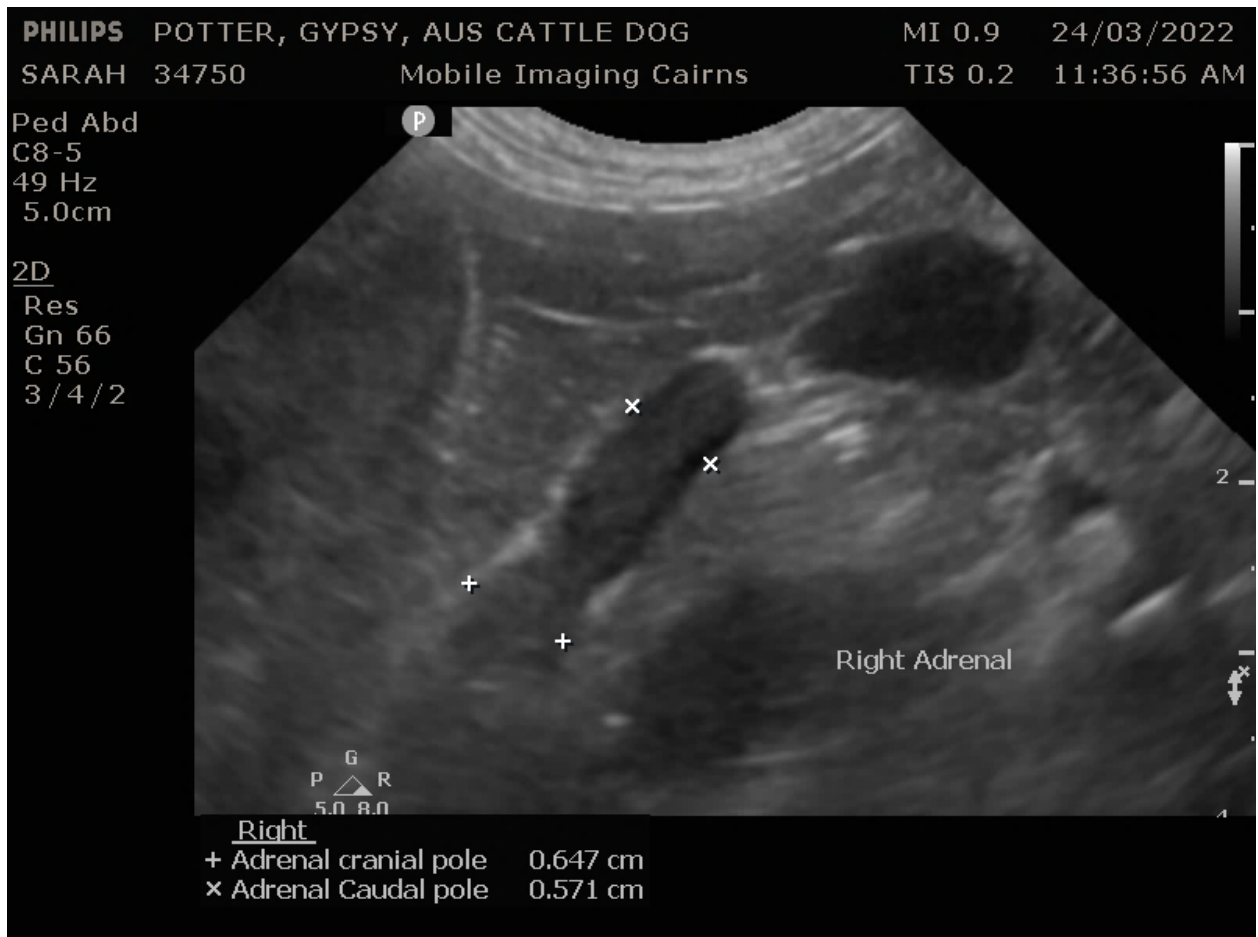
9. Left pancreas in longitudinal view, it is a normal shape with smooth margins, it is hypoechoic relative to its surrounds with a uniform echotexture. It measures 1.16cm in diameter. The stomach which contains gas can be seen to the left of the image and the colon filled with gas and faecal contents can be seen on the right.



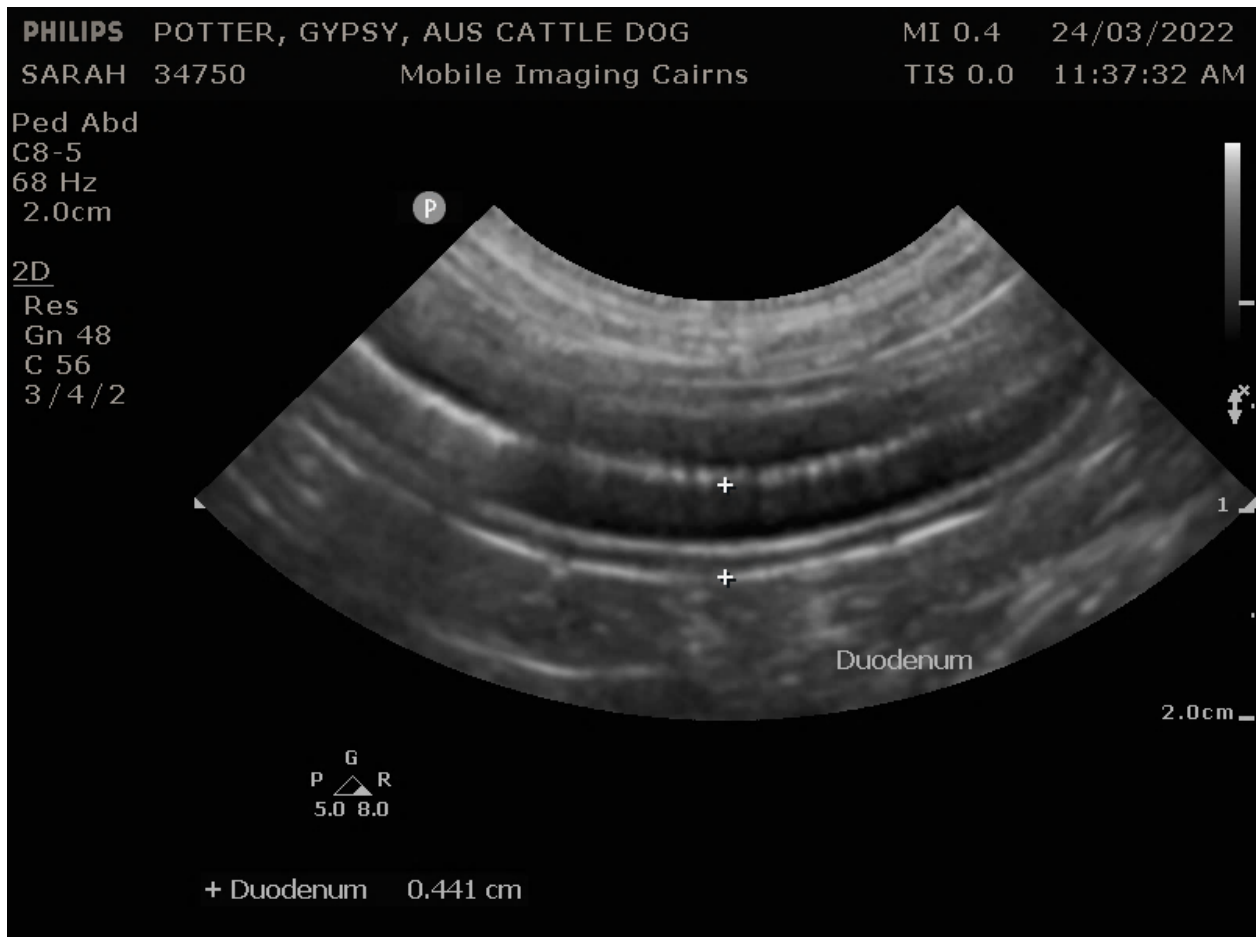
10. Longitudinal view of the right medial iliac lymph node. It is 0.392cm thick. It is normal in shape, has smooth margins, it is isoechoic relative to its surrounds.



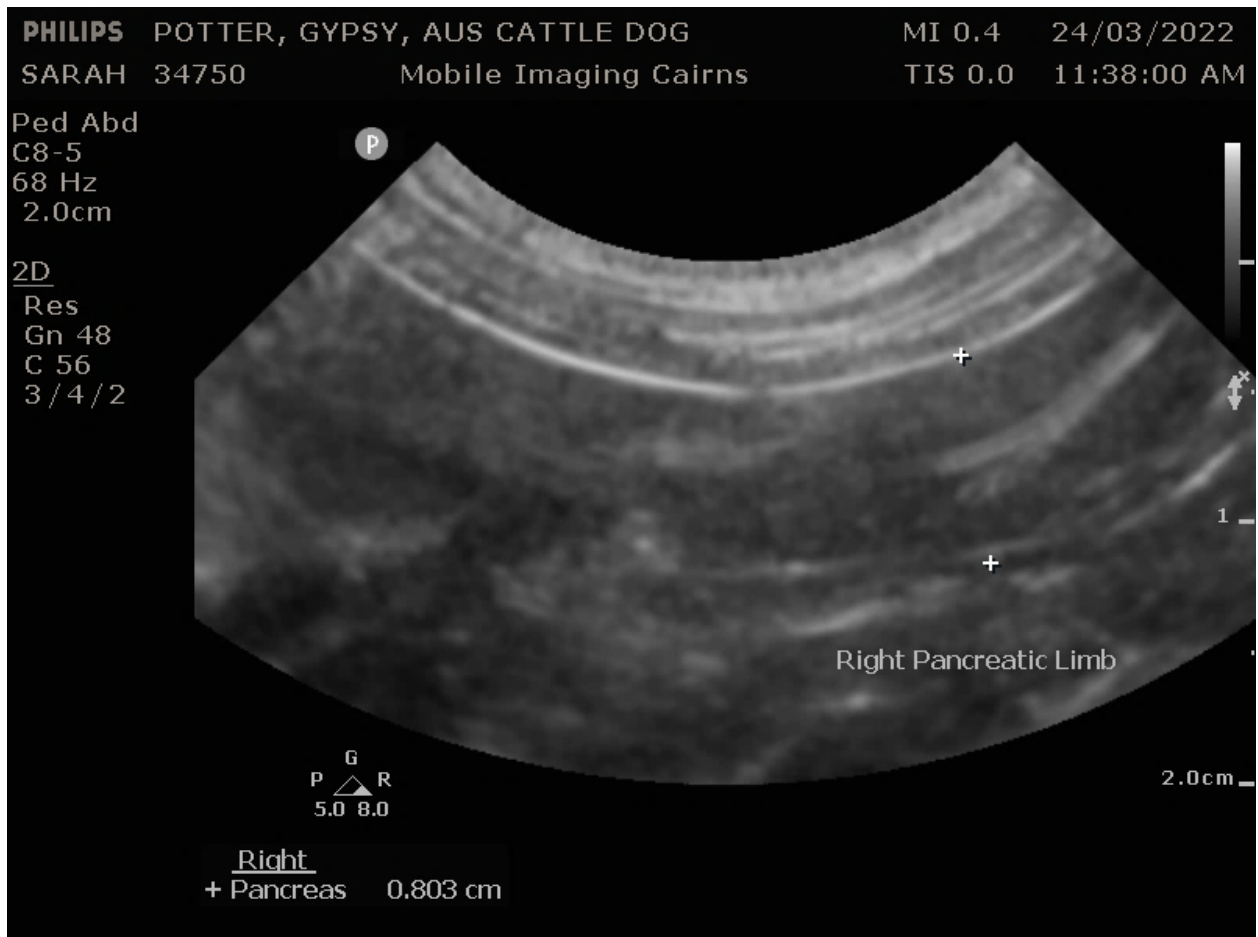
11. Right kidney dorsal view with measurement. There is good corticomedullary definition present with smooth regular margins. The length is 6.02cm and the height is 2.94cm. The kidney appears normal.



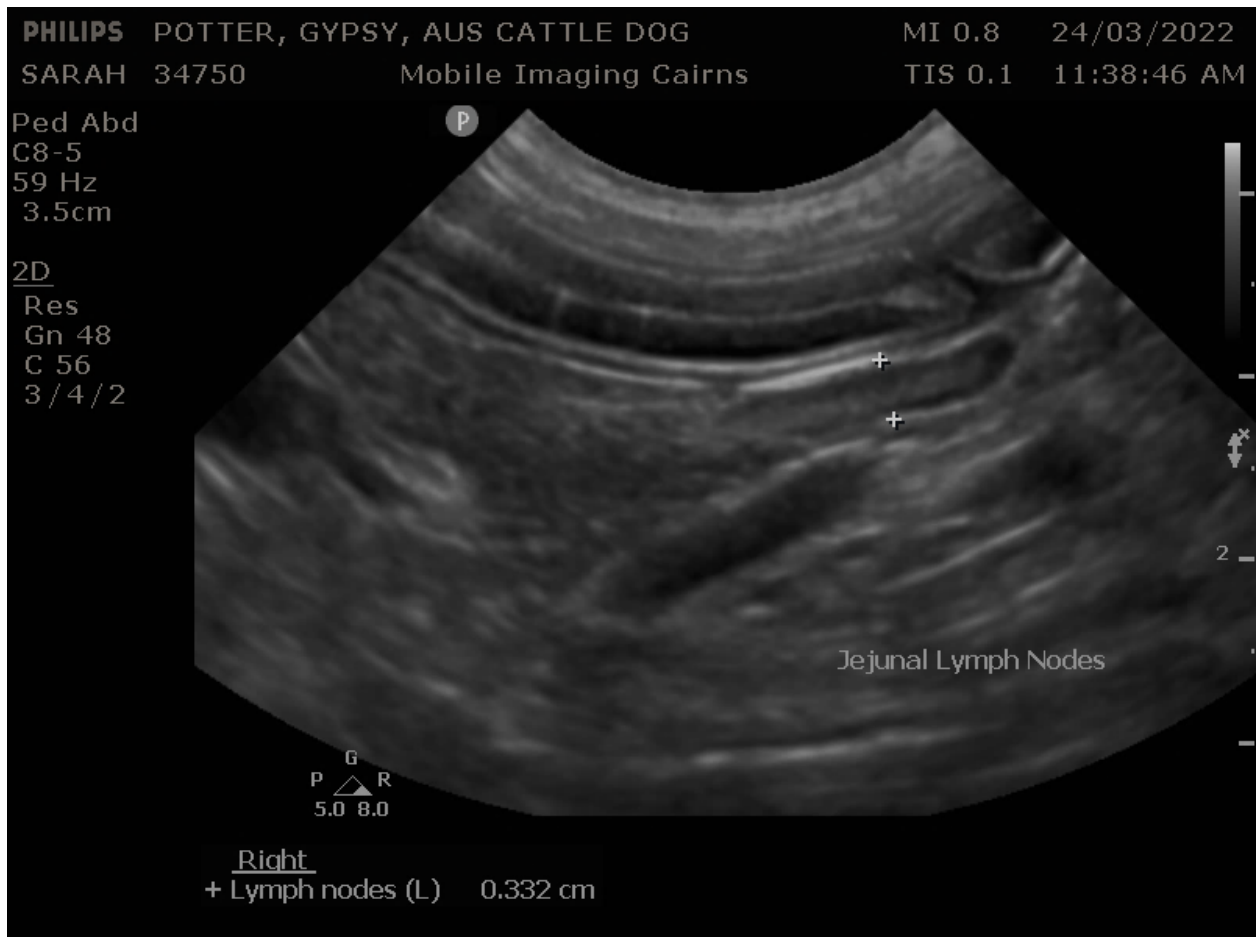
12. Right adrenal with measurements. The diameter of the cranial pole is 0.647cm and the diameter of the caudal pole is 0.571cm, this is within normal limits².



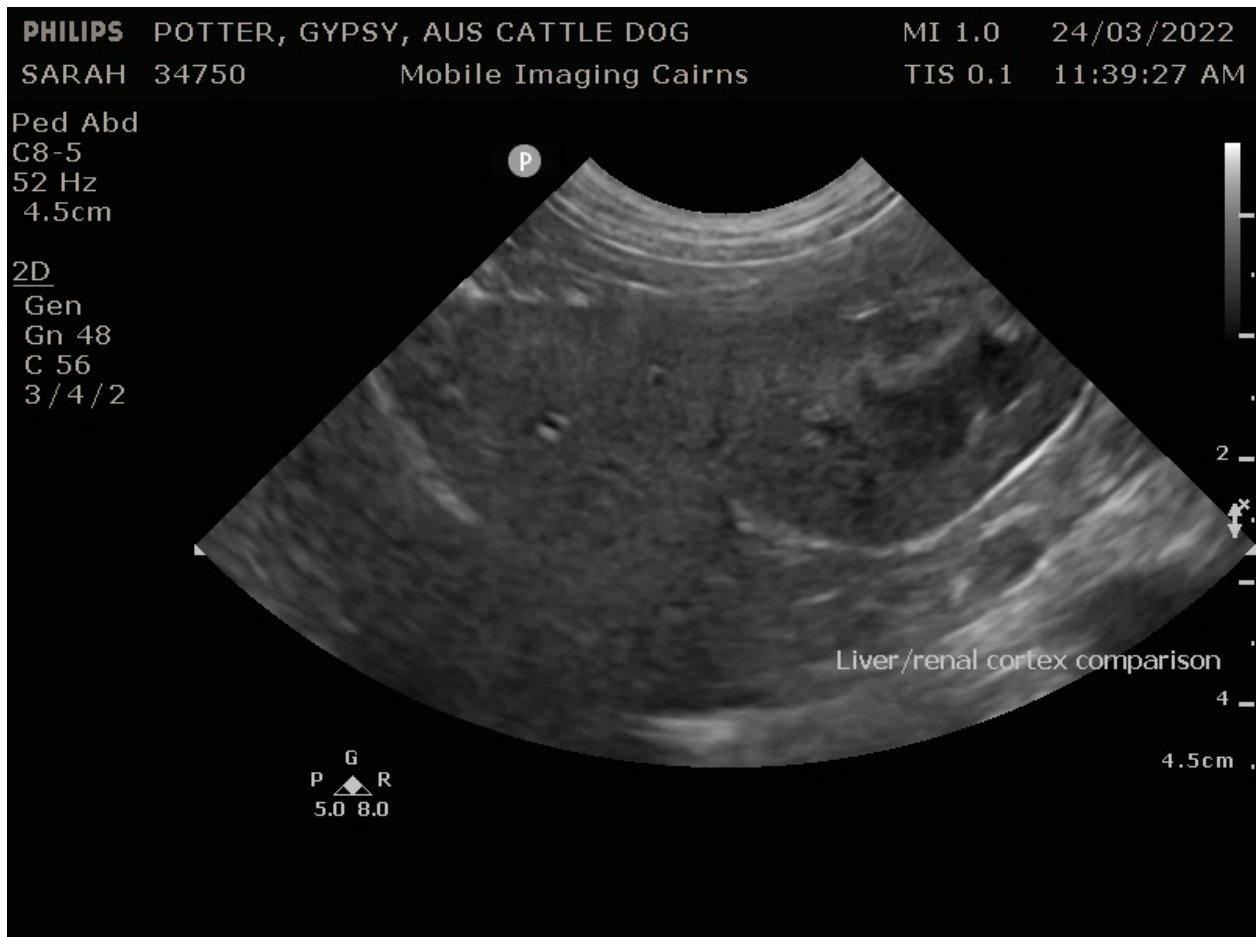
13. Longitudinal view of the duodenum, it measures 0.441cm in diameter, which is at the top end of the normal range². It has smooth margins and normal gut layering present.



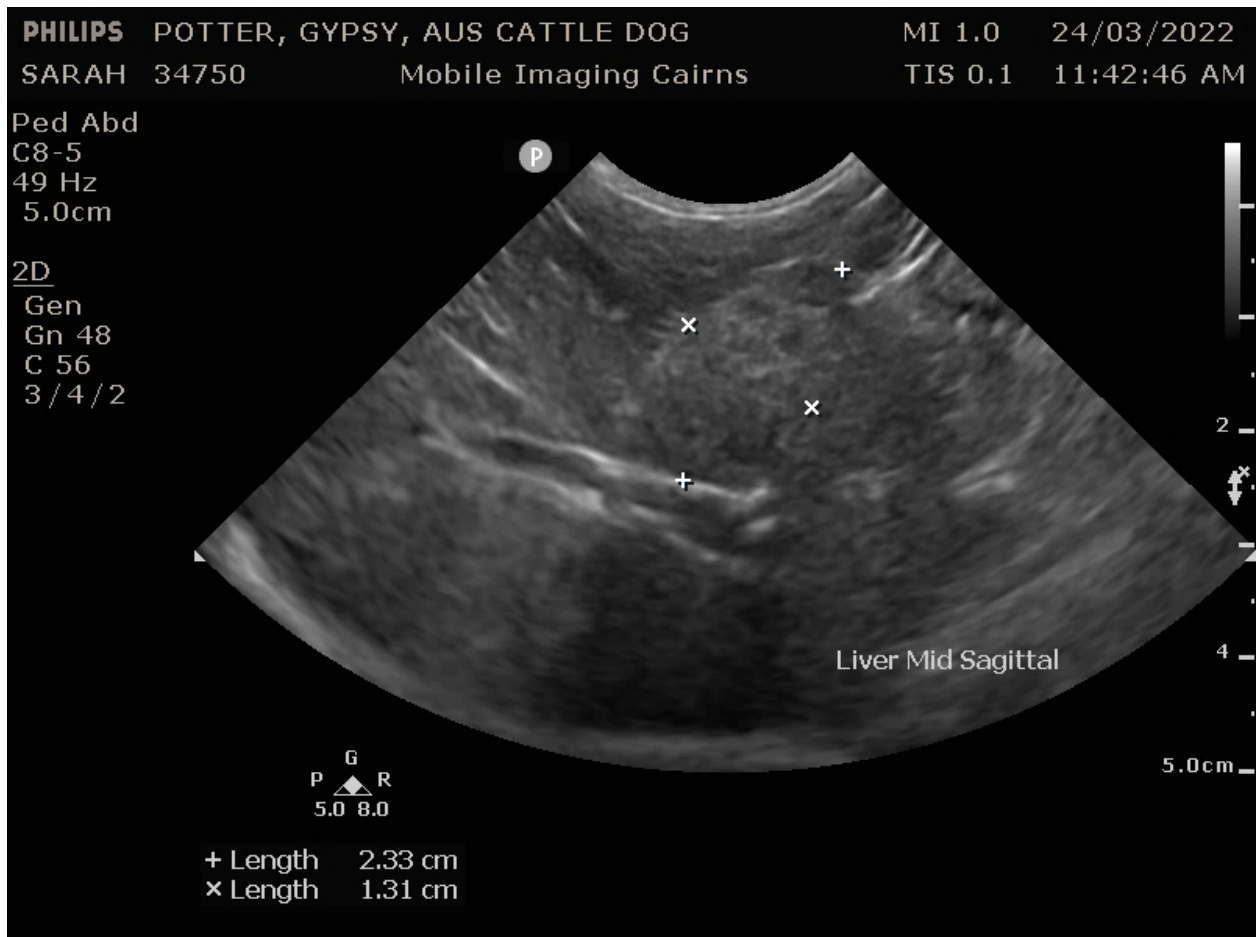
14. Right pancreatic limb in longitudinal section. It measures 0.803cm in diameter. It is isoechoic relative to its surrounds. It has a uniform echotexture.



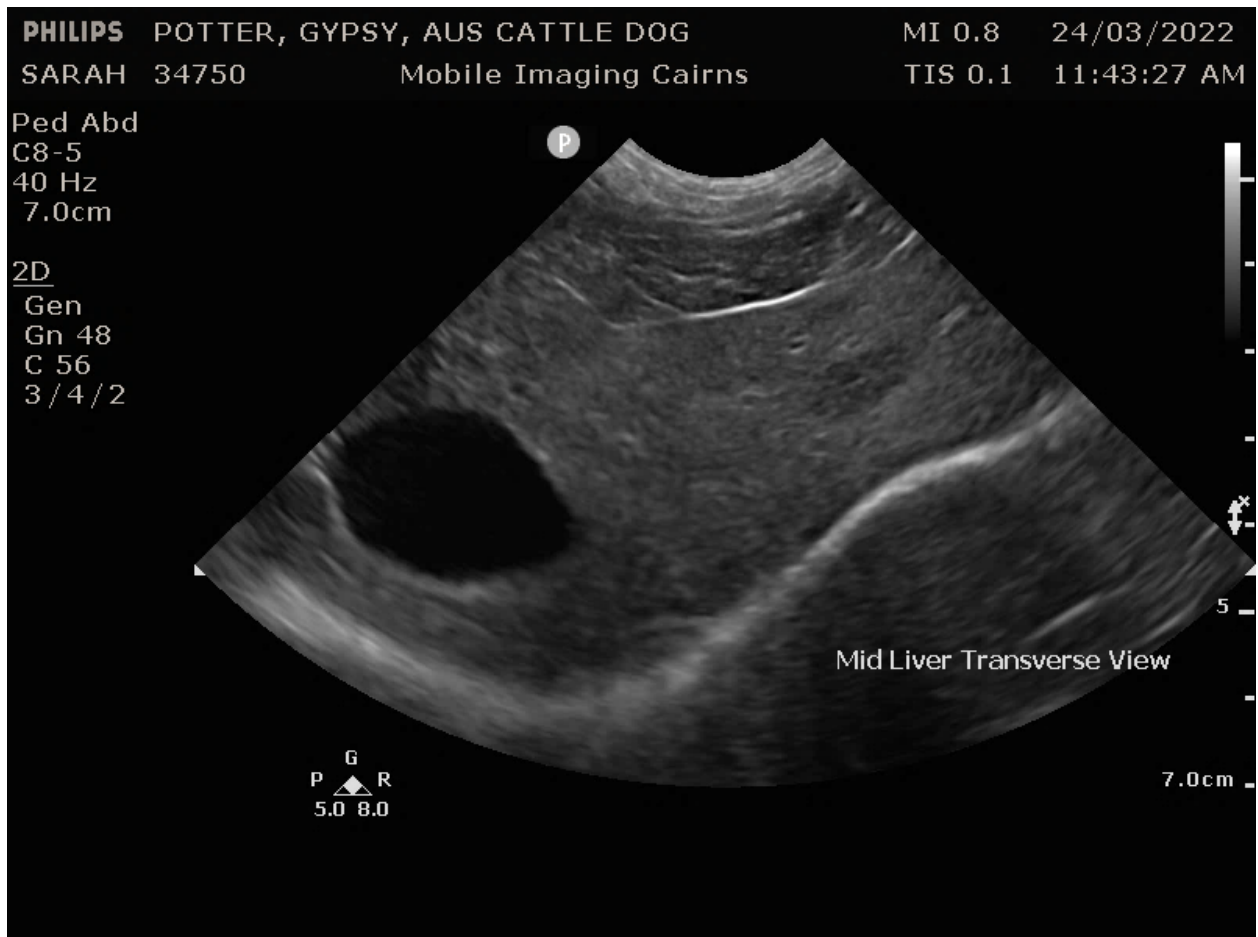
15. Longitudinal view of the jejunal lymph nodes. They measure 0.332cm in diameter and are isoechoic relative to their surrounds and appear normal.



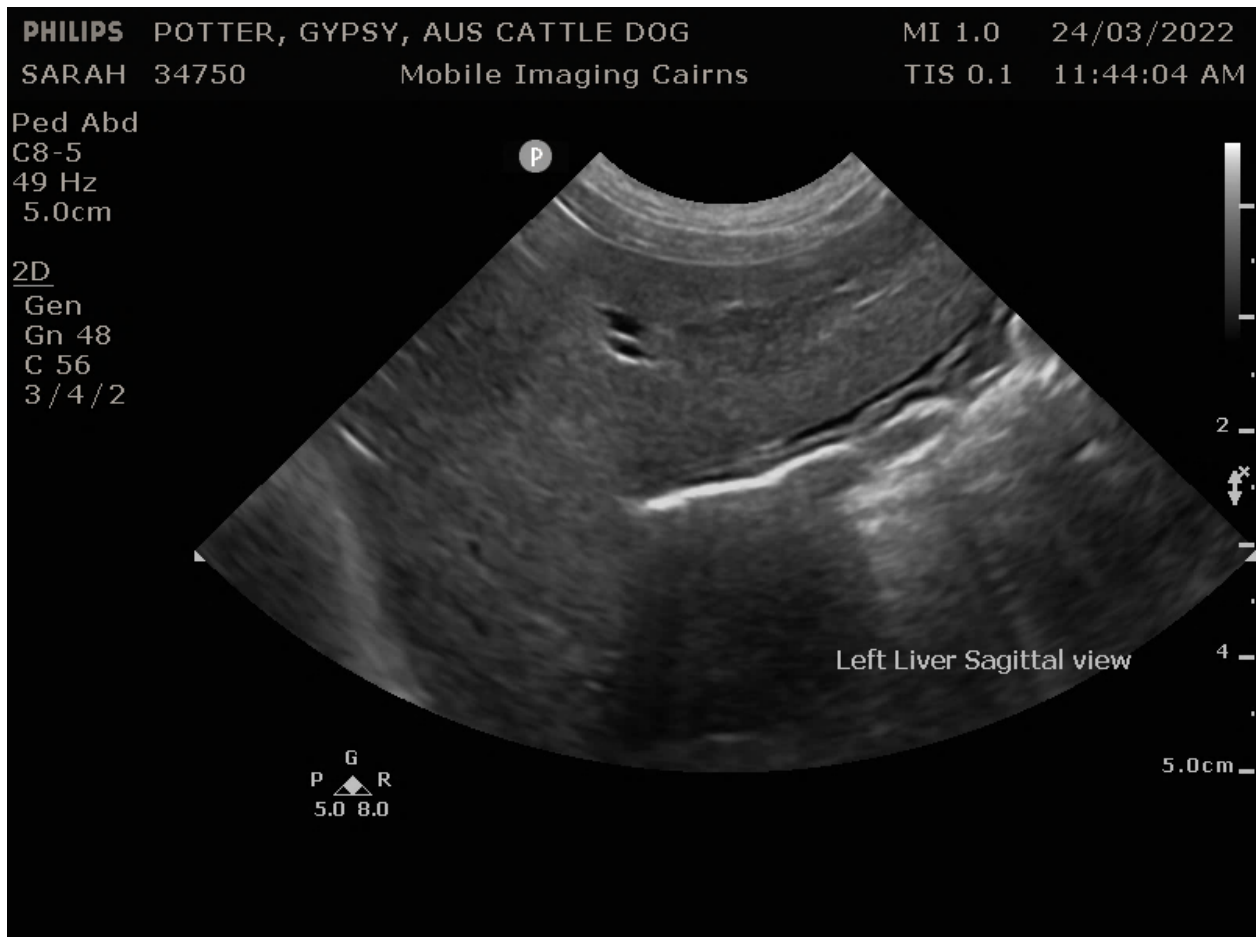
16. Right liver/right kidney comparison. At the same depth and gain settings the right renal cortex is isoechoic relative to the liver.



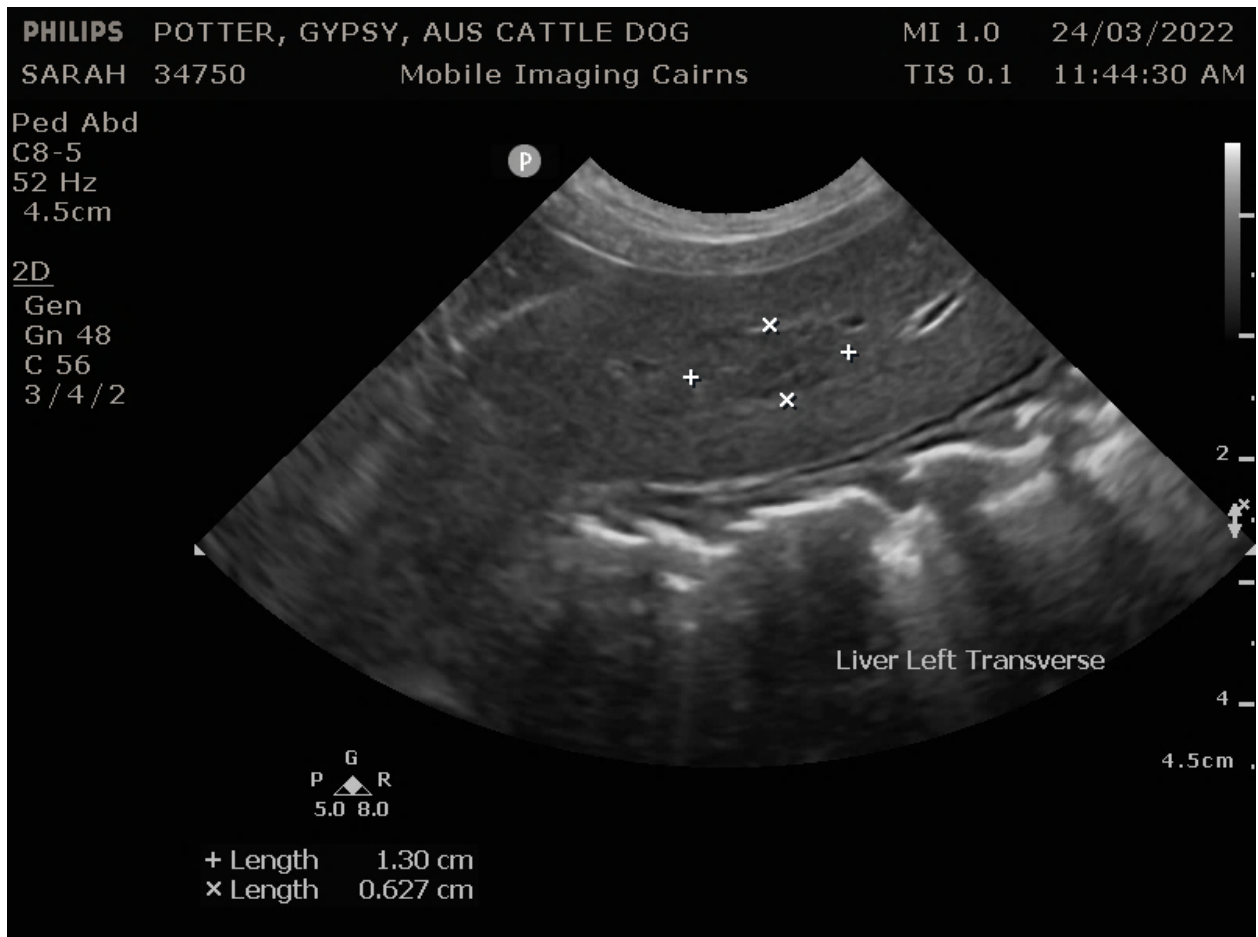
17. Sagittal midline image of the liver. There is a mass present which measures 2.33cm in diameter, it is roughly oval in shape. It is hypoechoic relative to surrounding liver with a mildly heterogeneous echotexture.



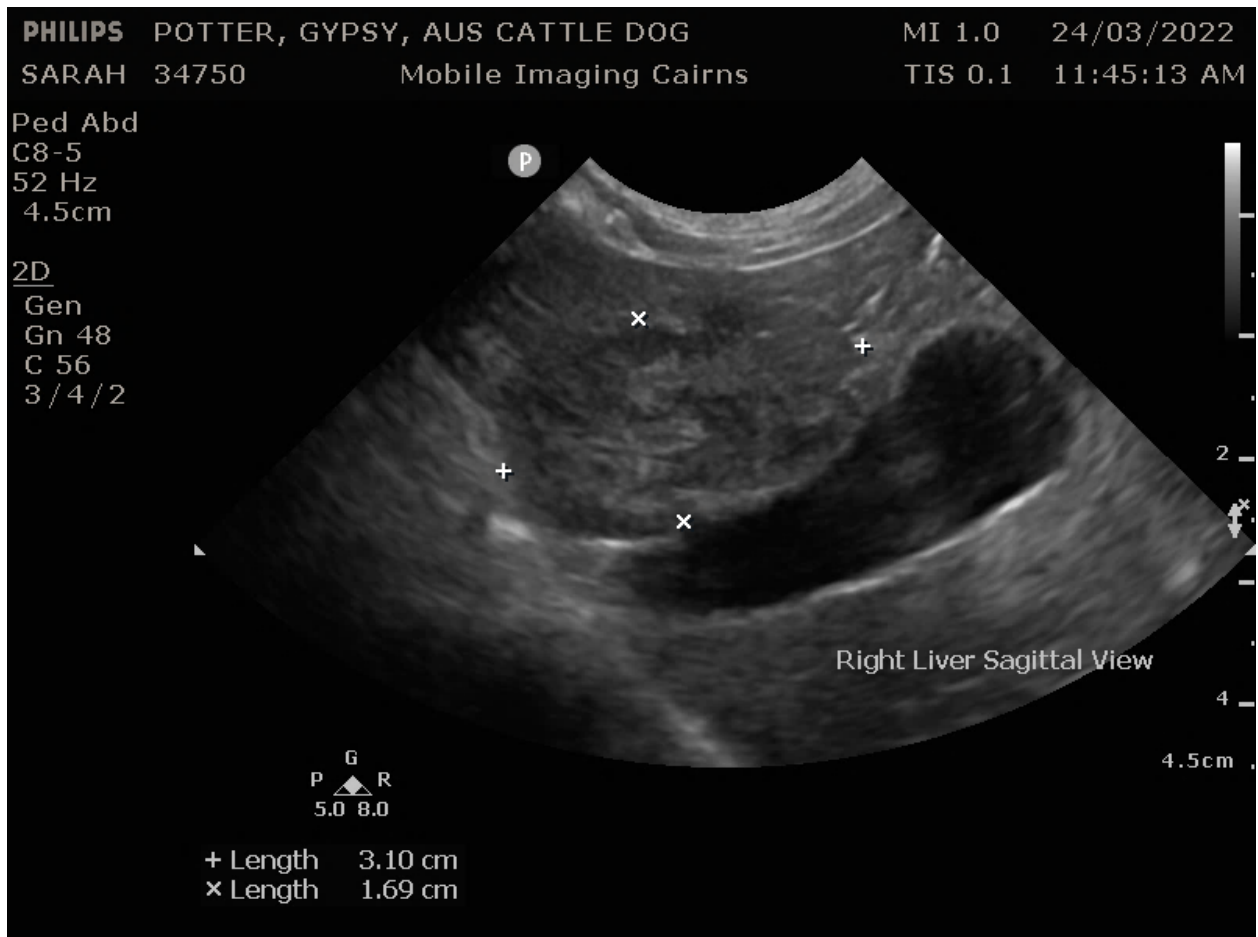
18. Transverse midline image of the liver. The margins are smooth, the diaphragm is intact and clearly seen. There are mildly hypoechoic nodules present in the parenchyma.



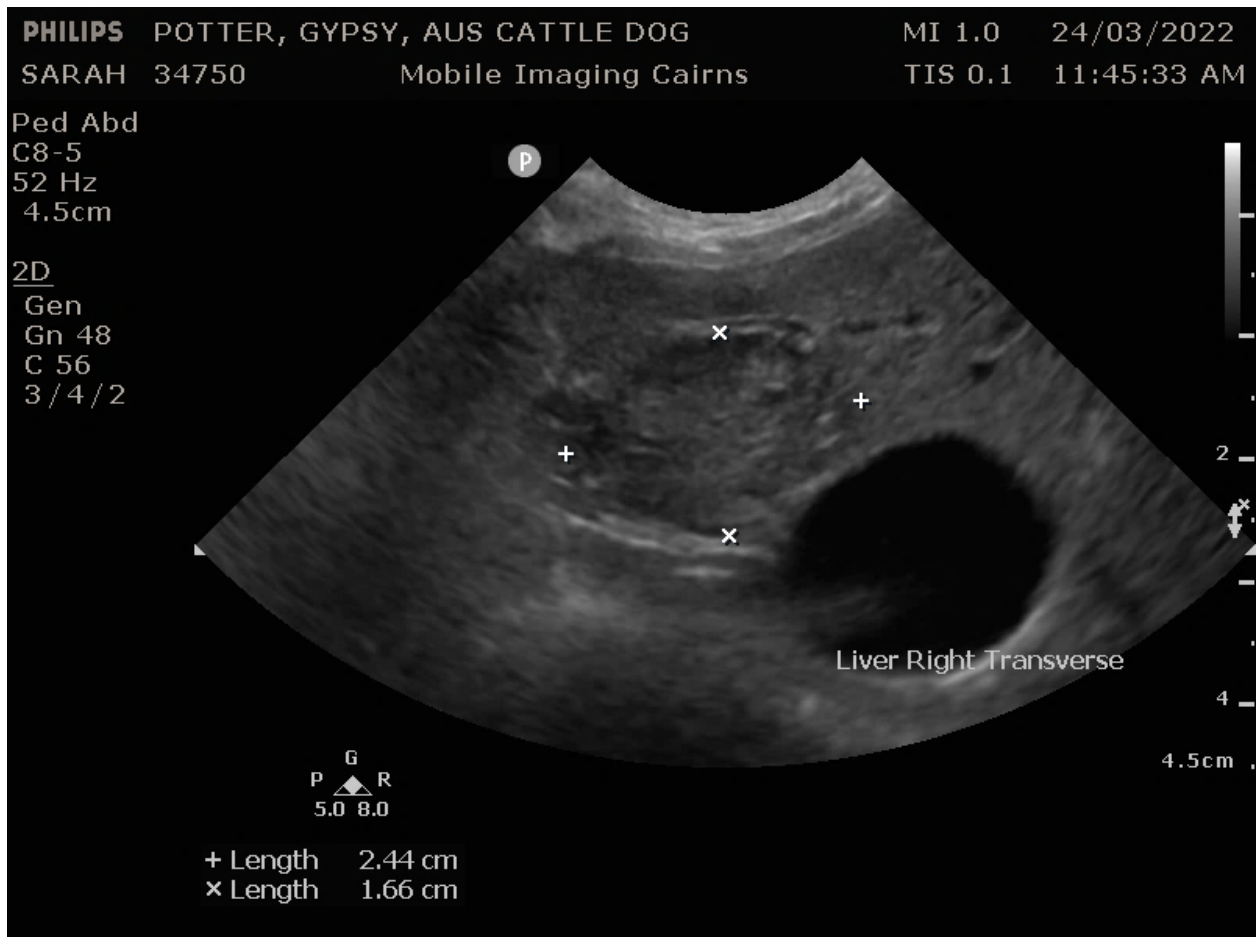
19. Sagittal image of the left lobes of liver, it is normal in appearance. The stomach with gas present can be seen in the mid field.



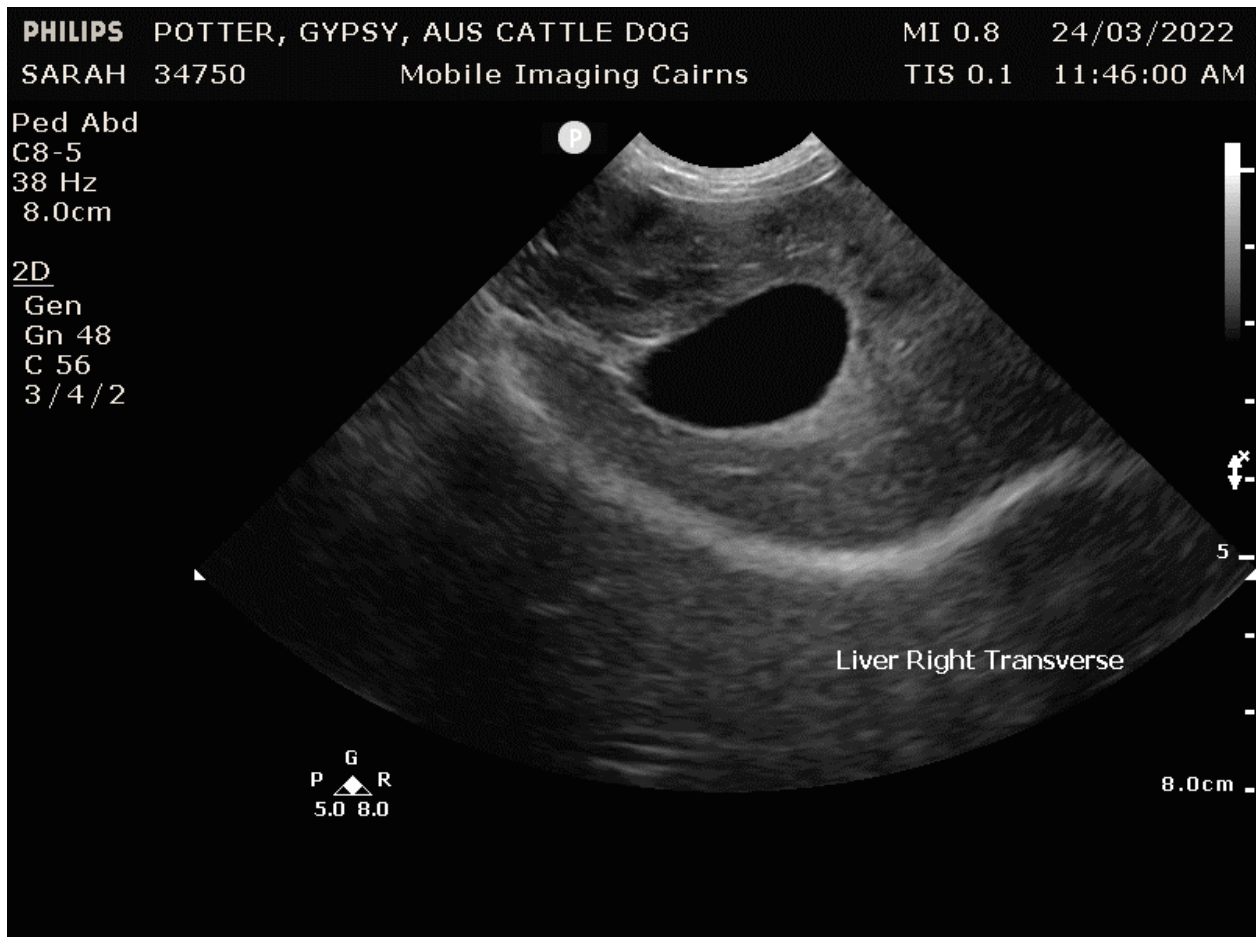
20. Transverse view of the left liver. There is a nodule present, it is roughly oval in shape and measures 1.3cm by 0.627cm. It has poorly defined margins. It is hypoechoic relative to its surrounds with a mildly heterogeneous echotexture.



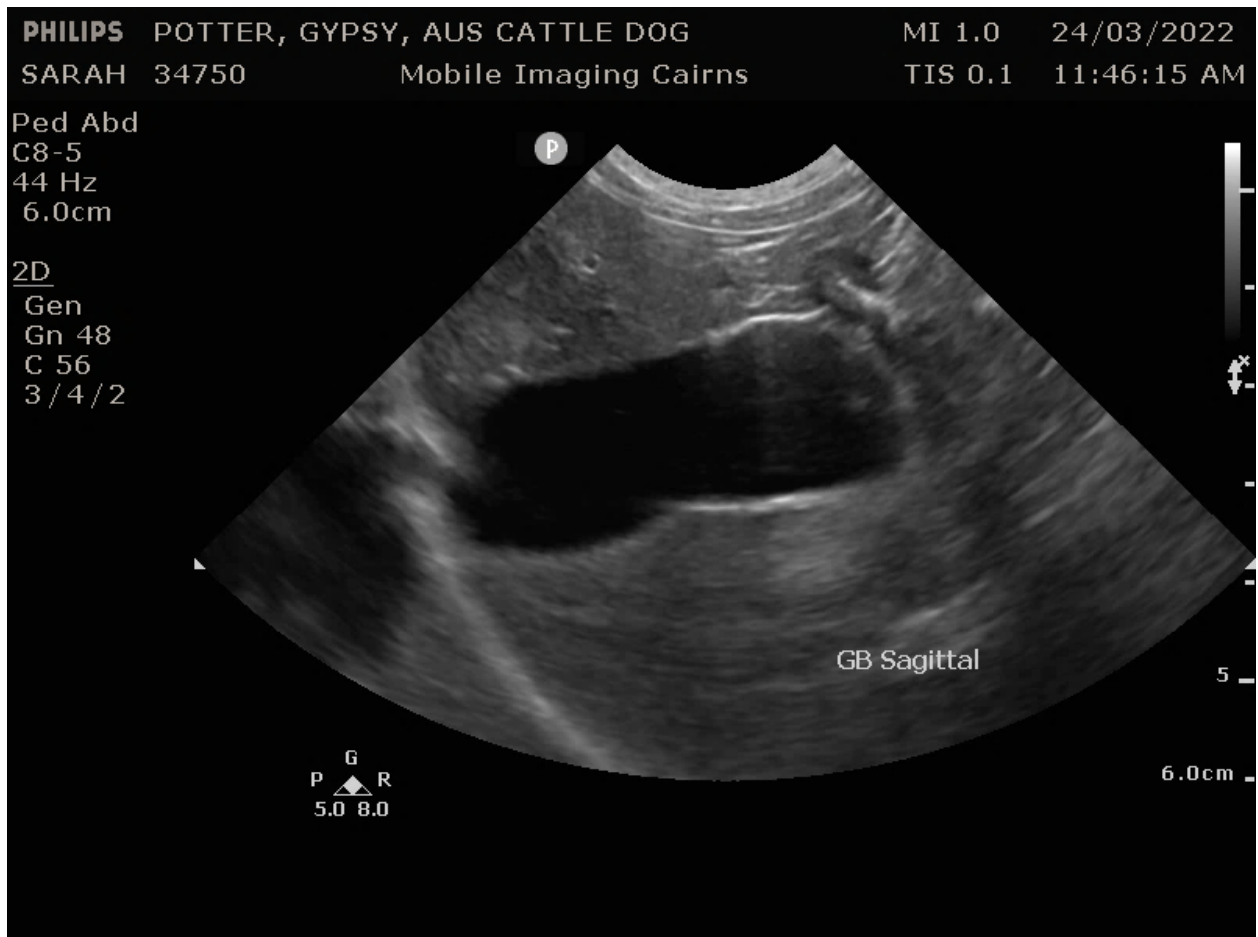
21. Right liver sagittal view. The gallbladder can be seen in this view, the contents are anechoic. Adjacent to the gallbladder is the mass seen in image 17. It is roughly oval in shape and measures 3.1cm by 1.69cm. It has smooth margins. It is hypoechoic relative to its surrounds with a heterogeneous echotexture



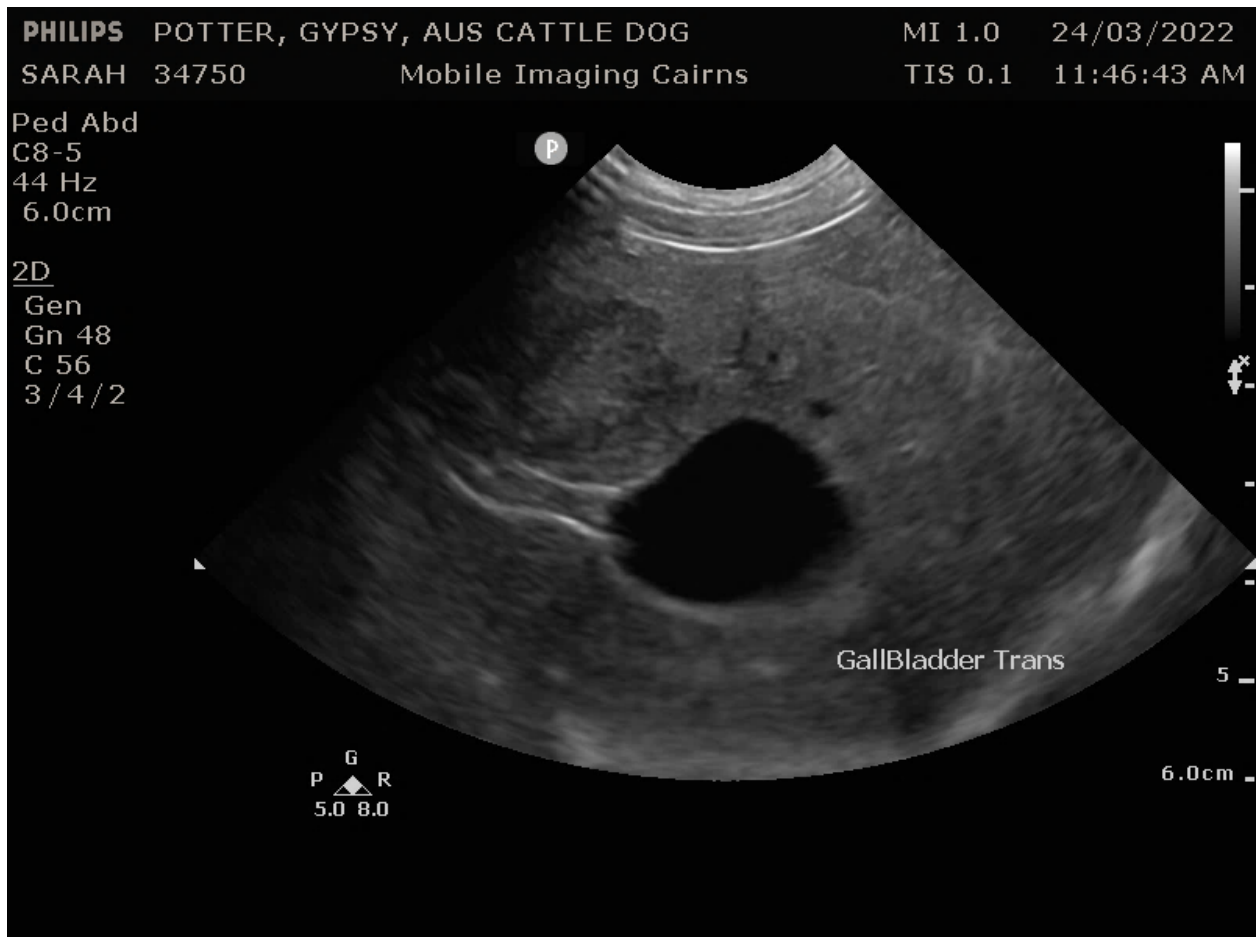
22. Transverse view of the right liver. The mass seen in images 17 and 21 is present in transverse view. it measures 2.44cm by 1.66cm. It has poorly defined margins. It is hypoechoic relative to its surrounds with a heterogeneous echotexture



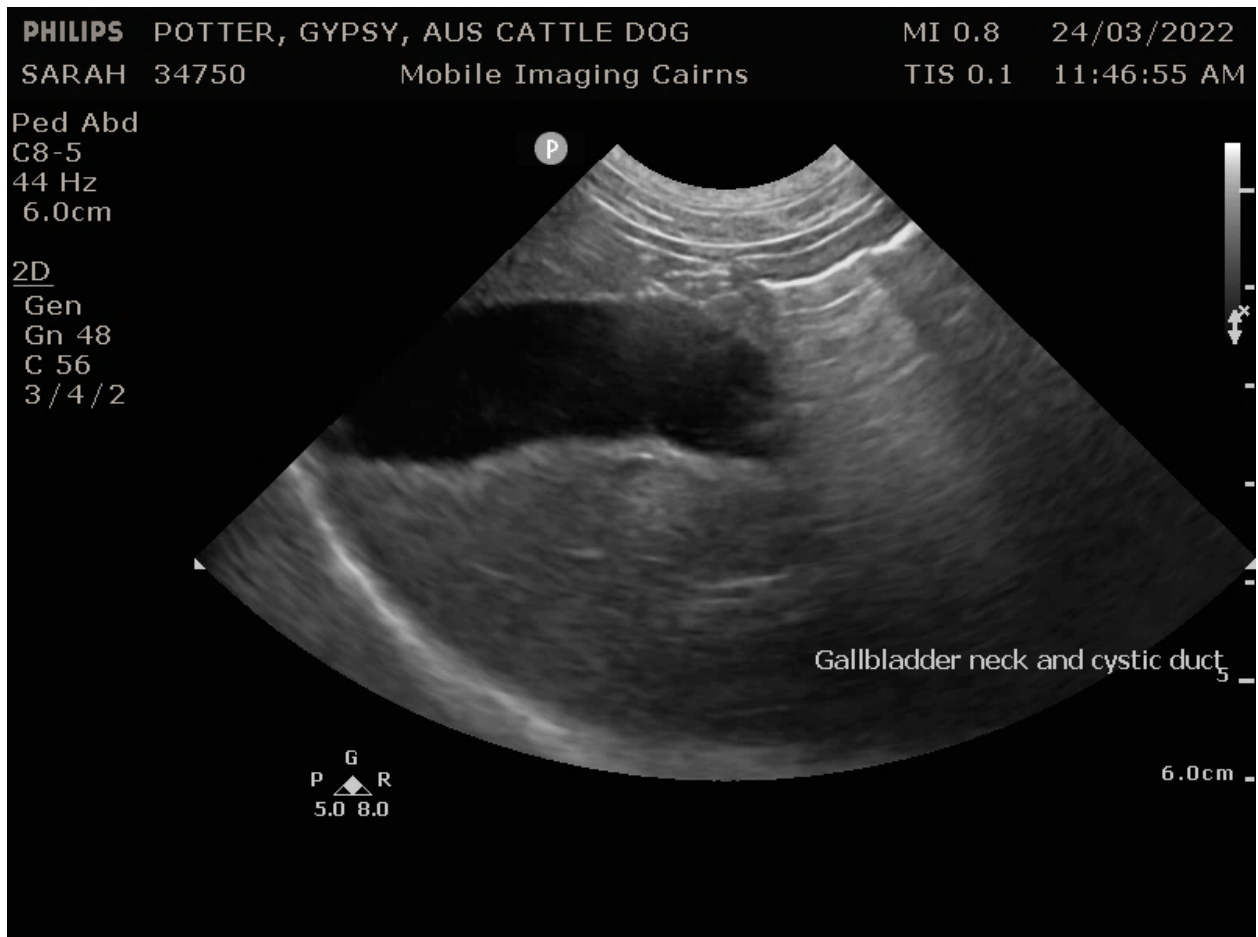23. Transverse image of the right lobes of liver, the mass described above can be seen in the near field. The gallbladder is present mid field, and the diaphragm can be seen in the far field, there are mildly hypoechoic nodules throughout the parenchyma.



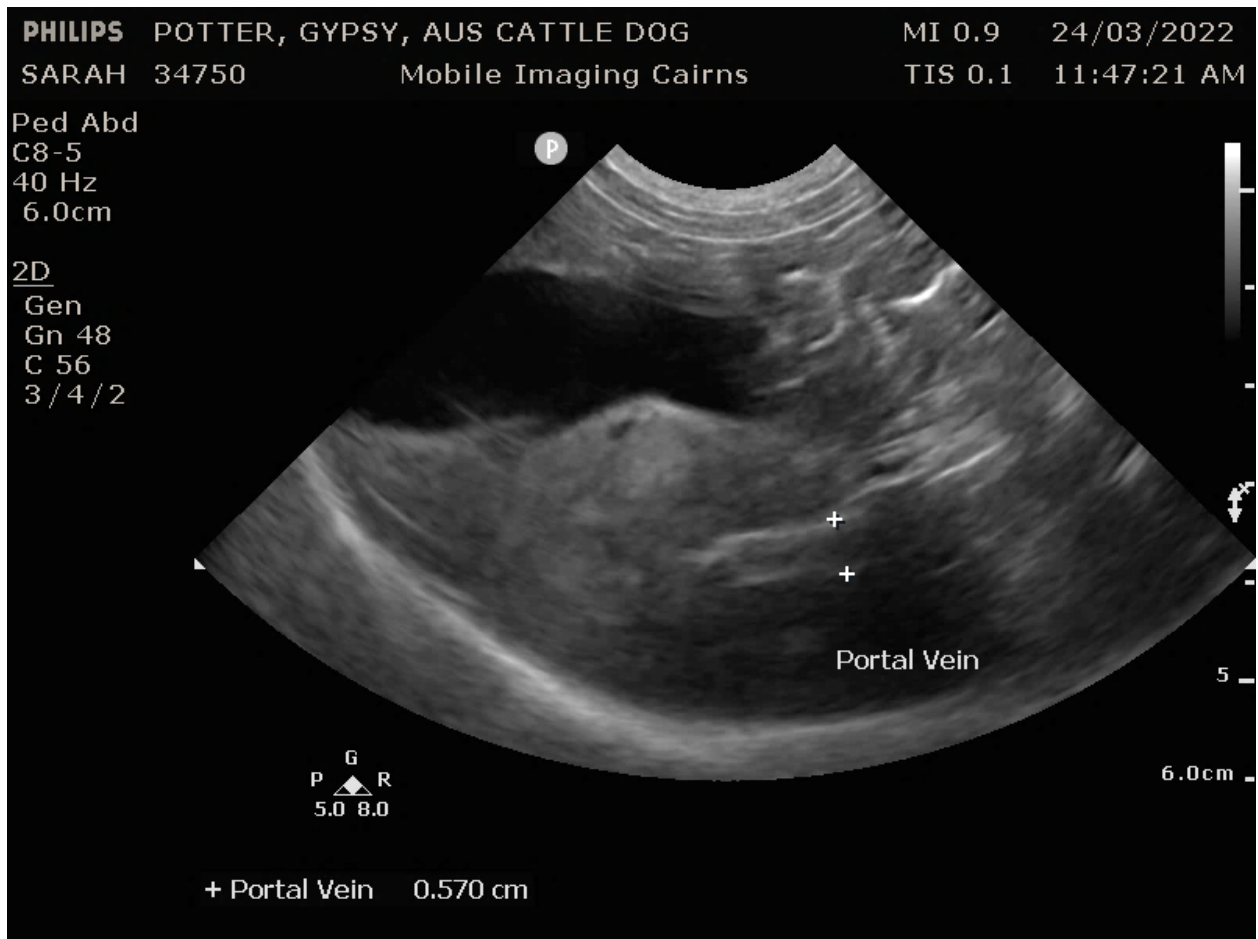
24. Sagittal view of the gallbladder. The shape is normal. the walls are thin and smooth. The contents are anechoic which is normal.



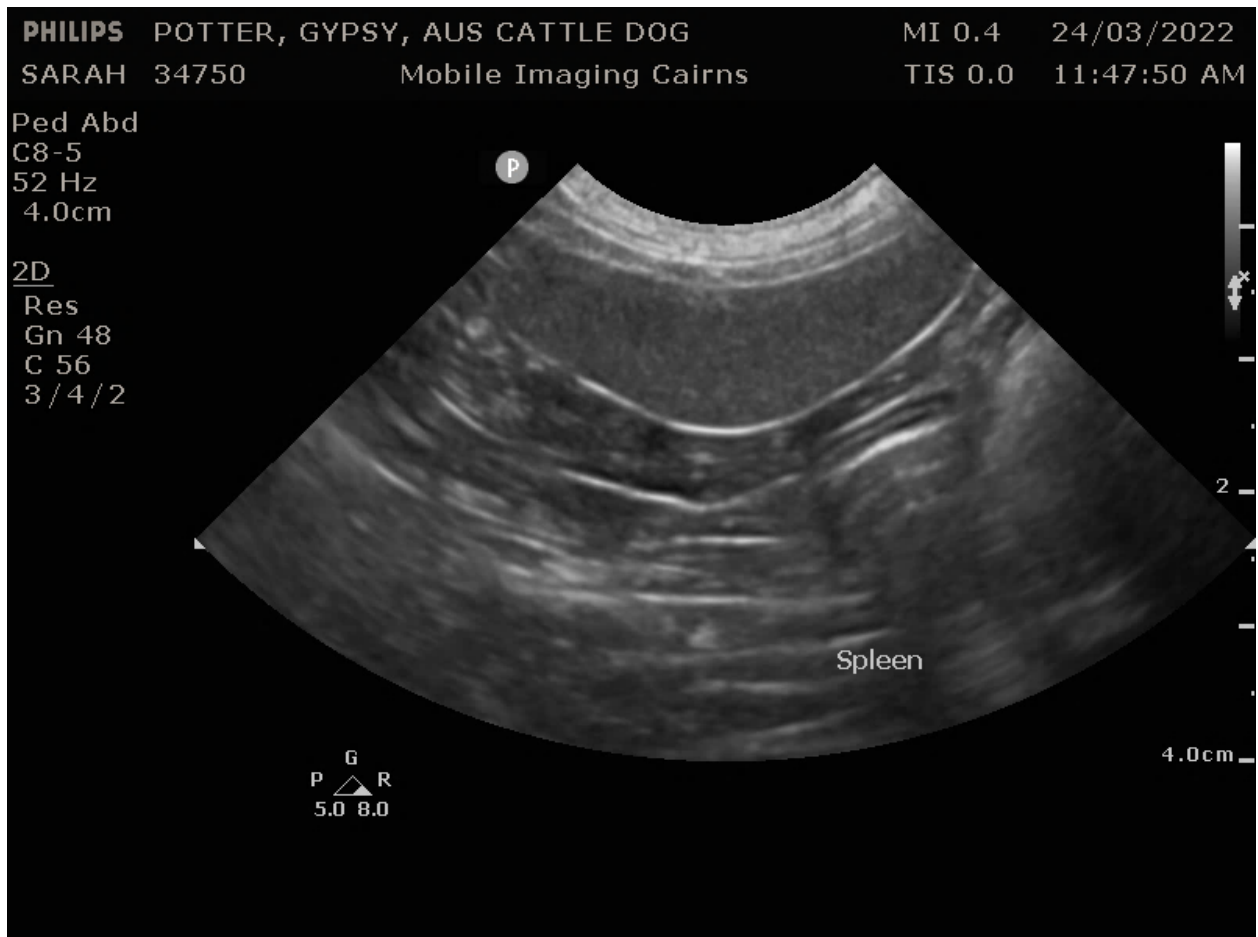
25. Transverse view of the gallbladder. The contents are anechoic which is normal. The mass described in 17, 21 and 22 can be seen immediately to the left of the gallbladder in the quadrate lobe, it appears to be distorting the gallbladder wall in this view.



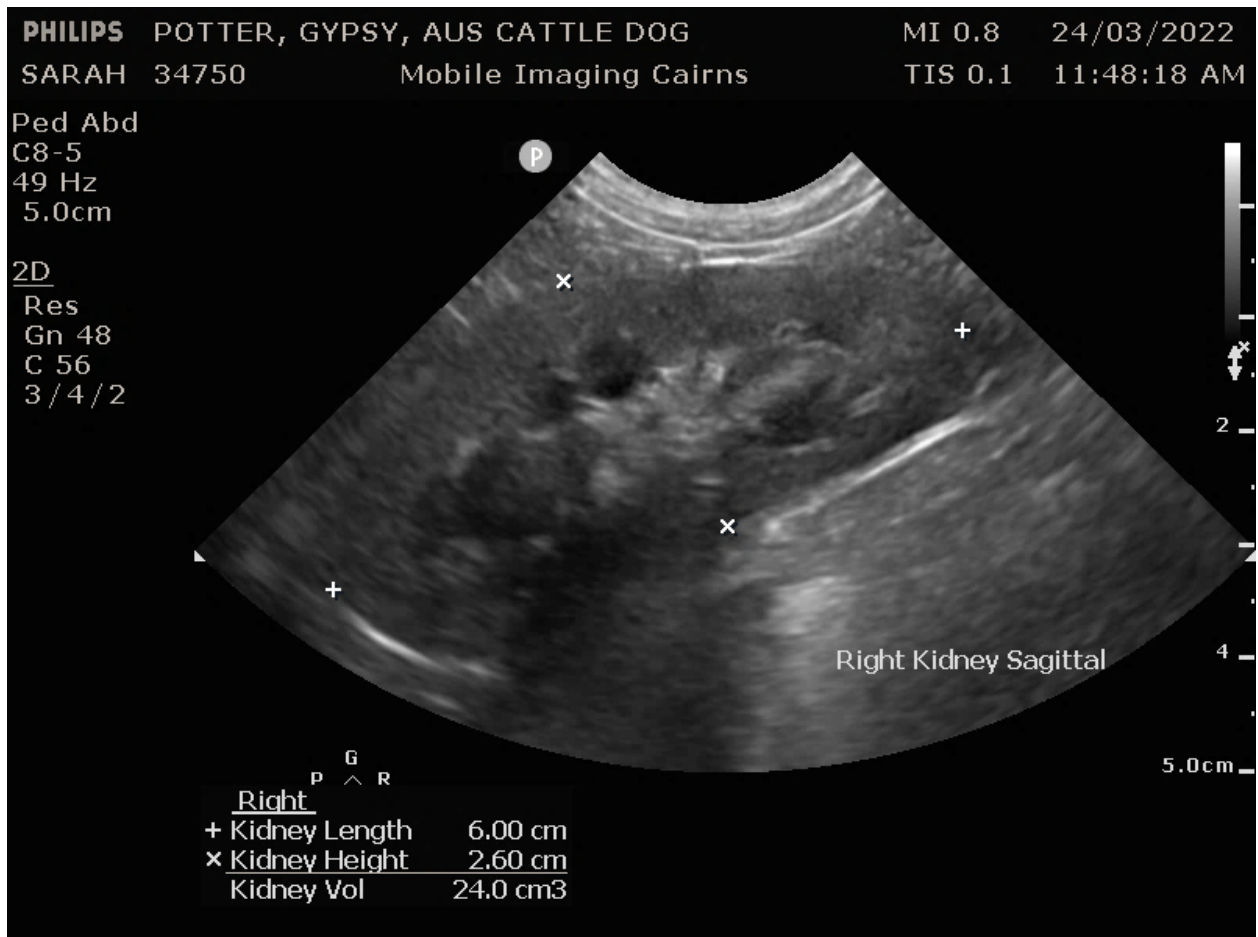
26. Sagittal view of the gallbladder neck, which appears normal. Intestinal gas can be seen to the right of the image and is obscuring a clear view of this region.



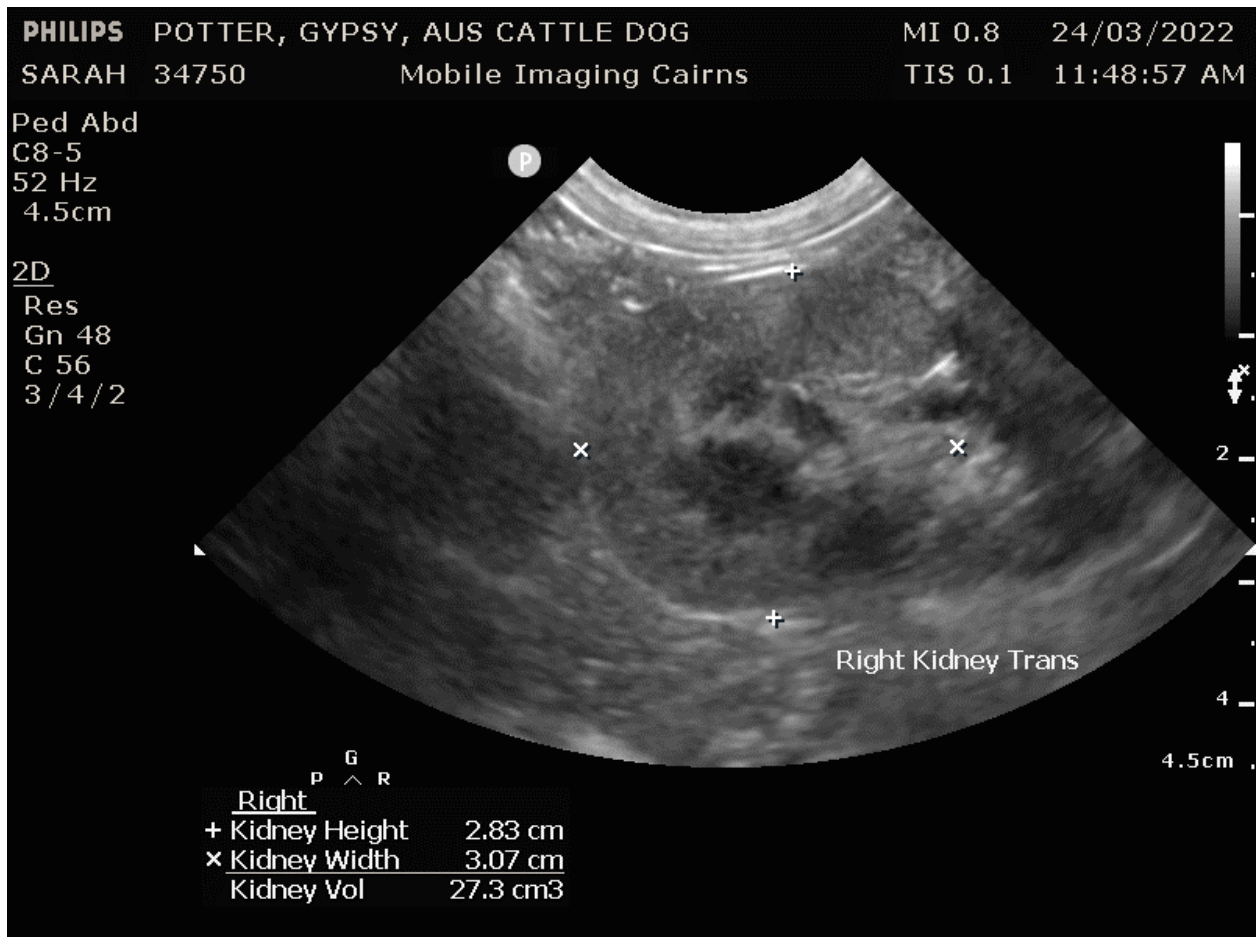
27. The portal vein in longitudinal view, this measures 0.570cm and appears normal.



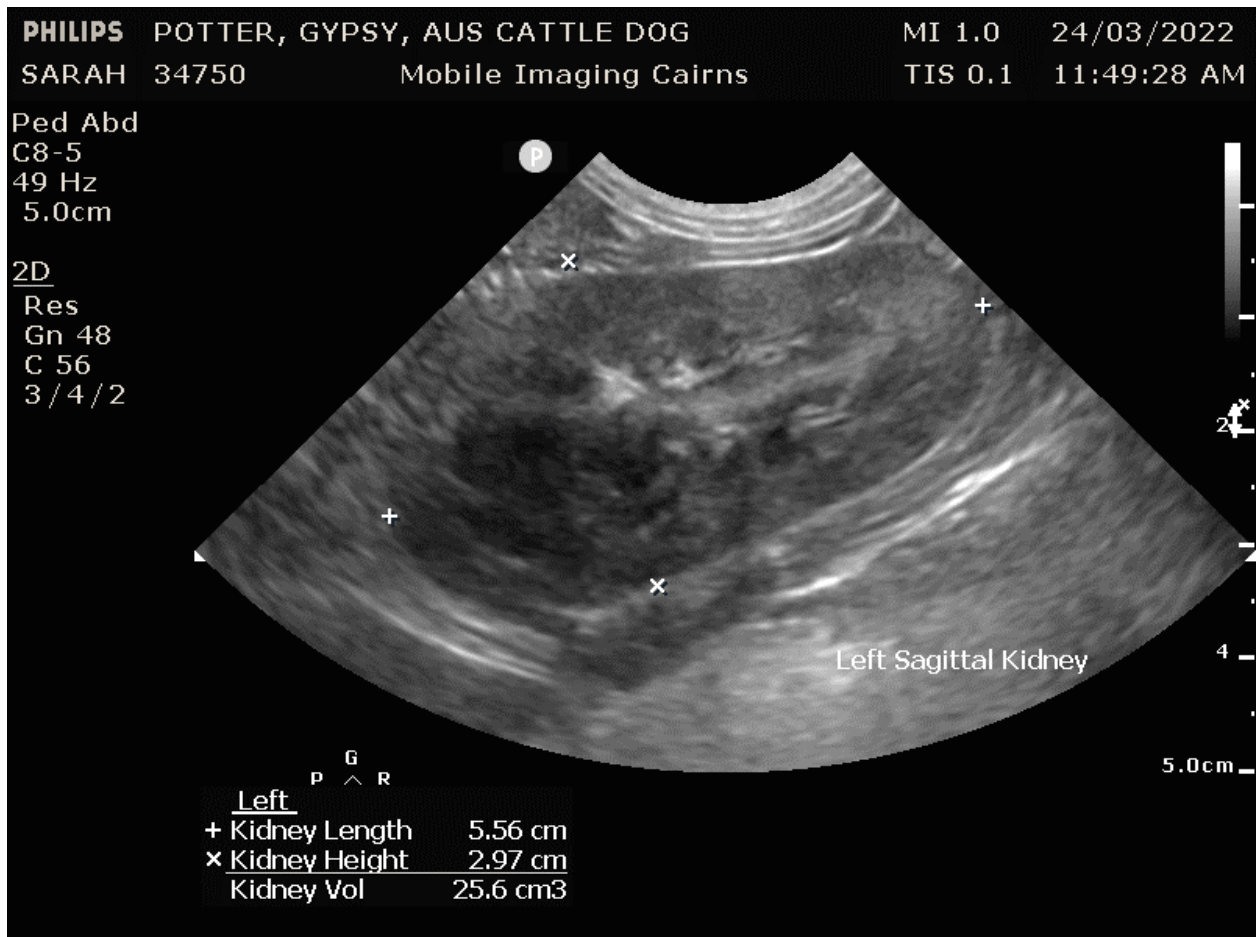
28. Transverse view of the spleen. The shape is normal, the margins are smooth, the echotexture is uniform.



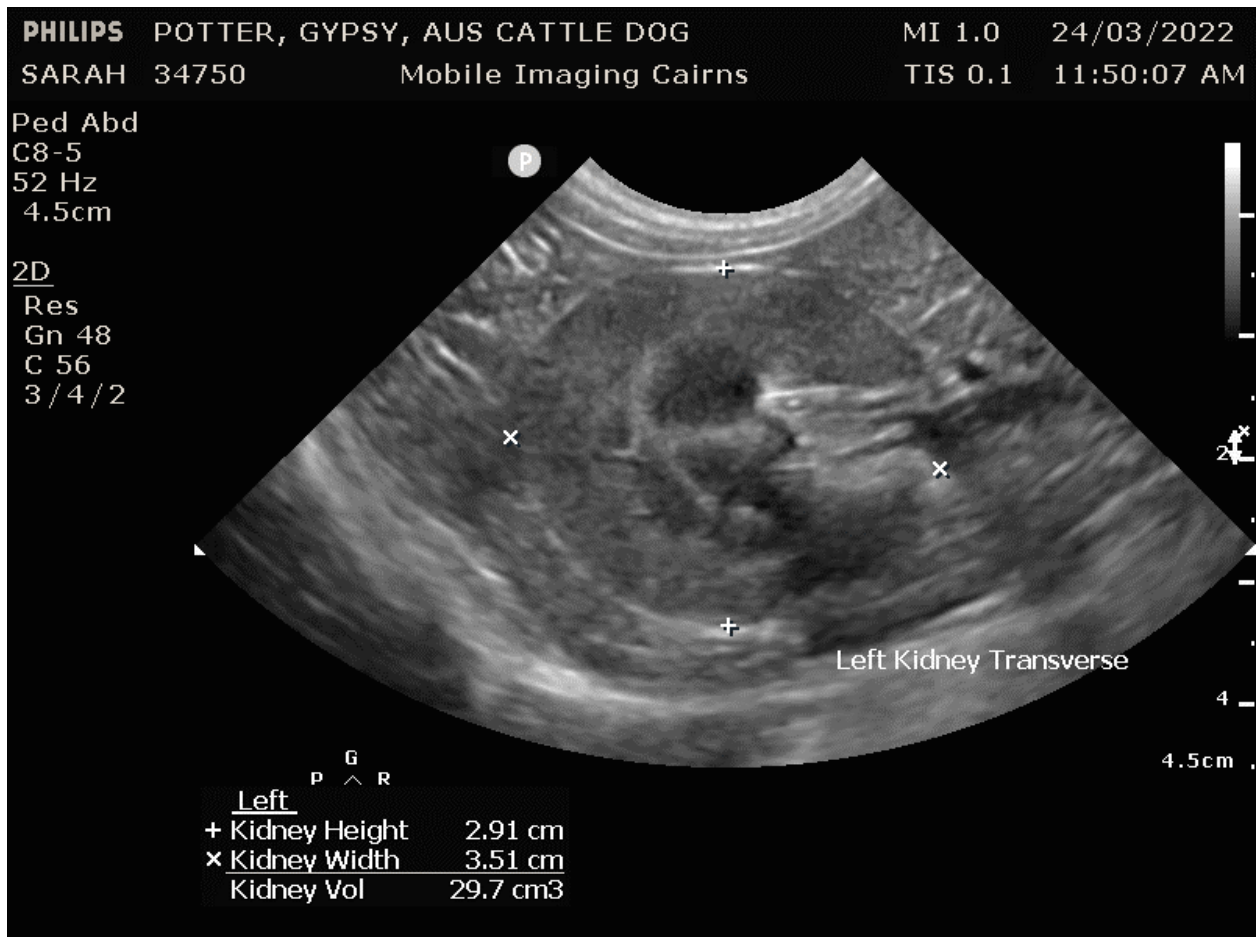
29. Right kidney sagittal with measurement. The length is 6.0cm and the height is 2.6cm. The appearance is normal.



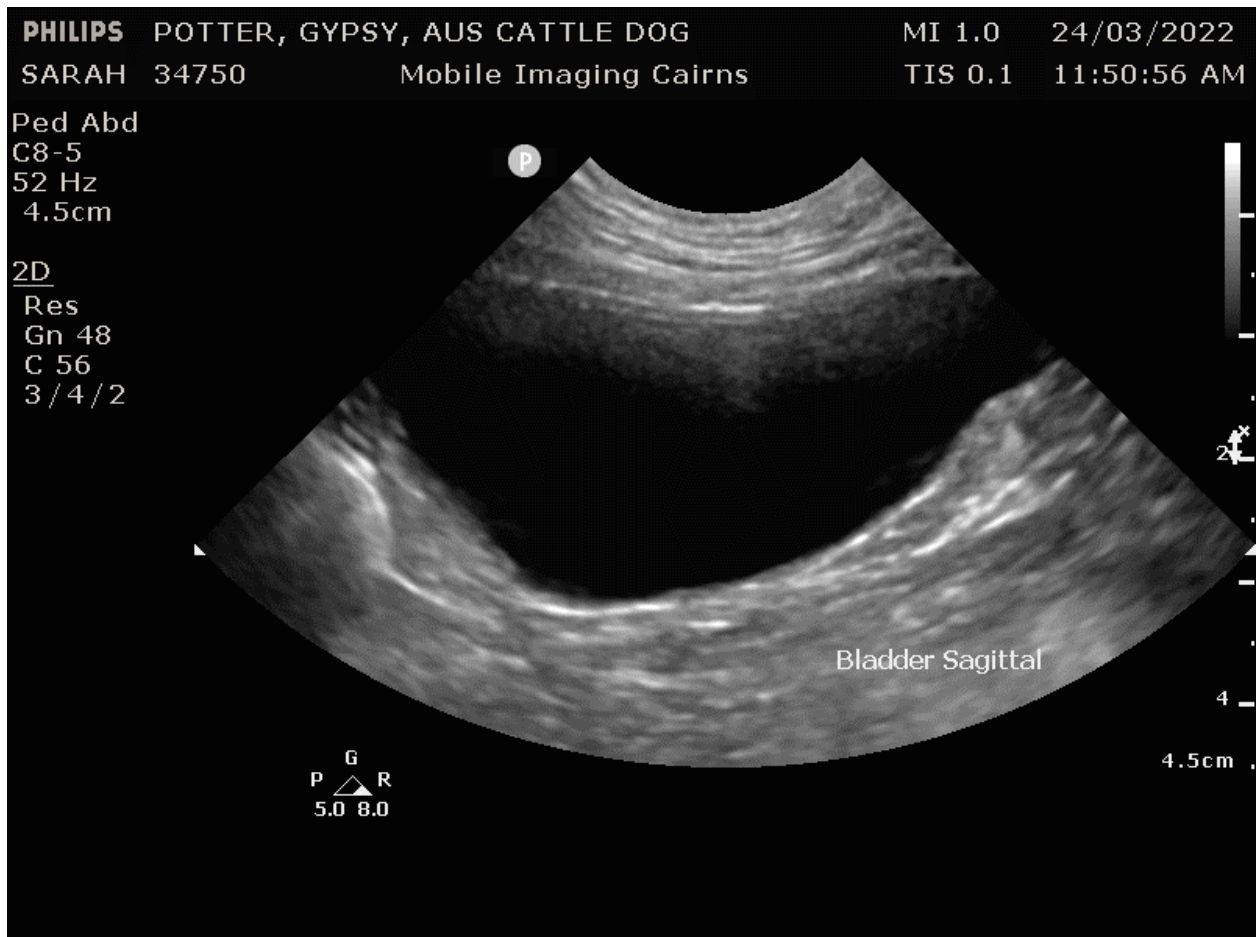
30. Right kidney transverse view with measurement. The height is 2.83cm and the width is 3.07cm. The appearance is normal.



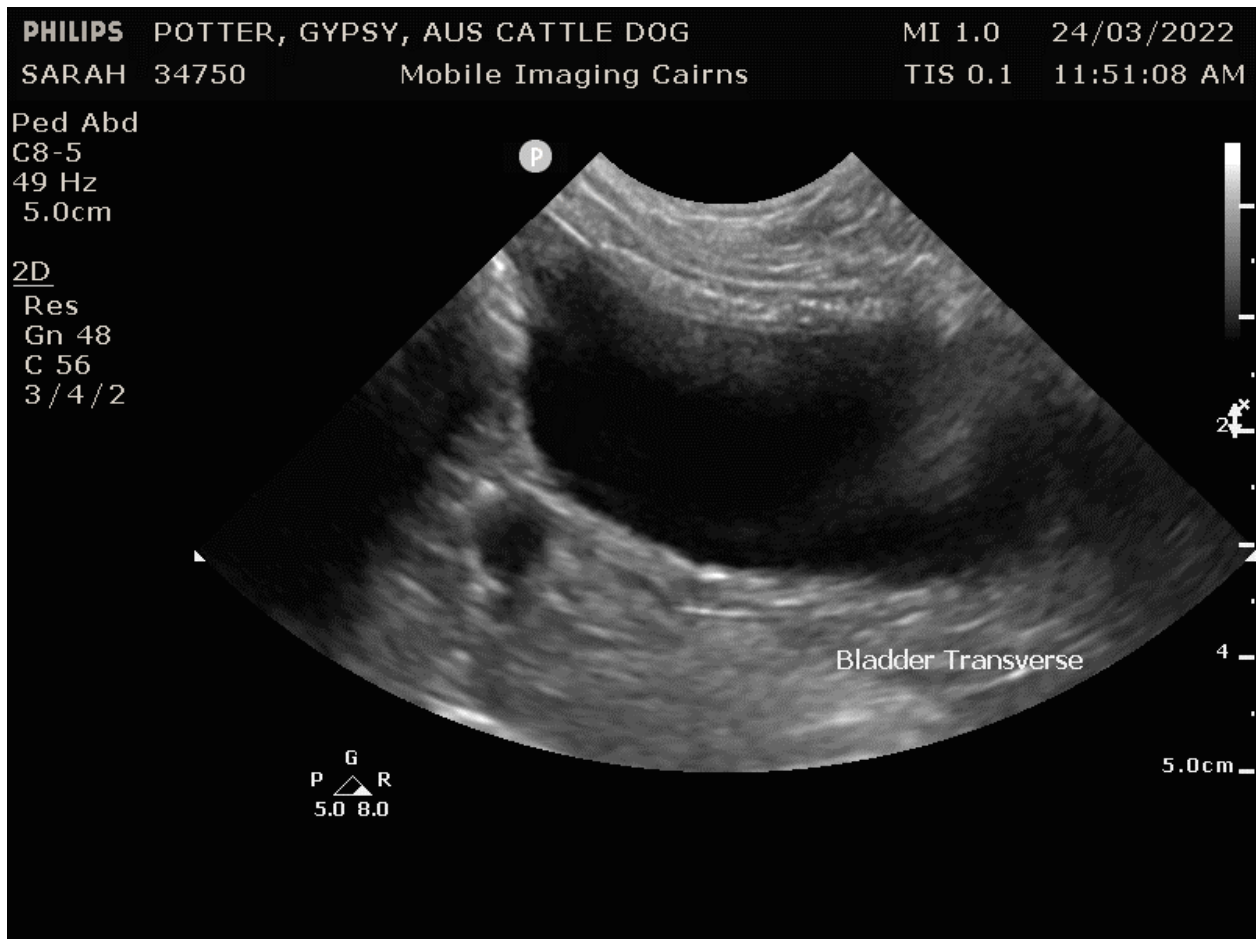
31. Left kidney sagittal view with measurement. The length is 5.56cm and the height is 2.97cm. The appearance is normal.



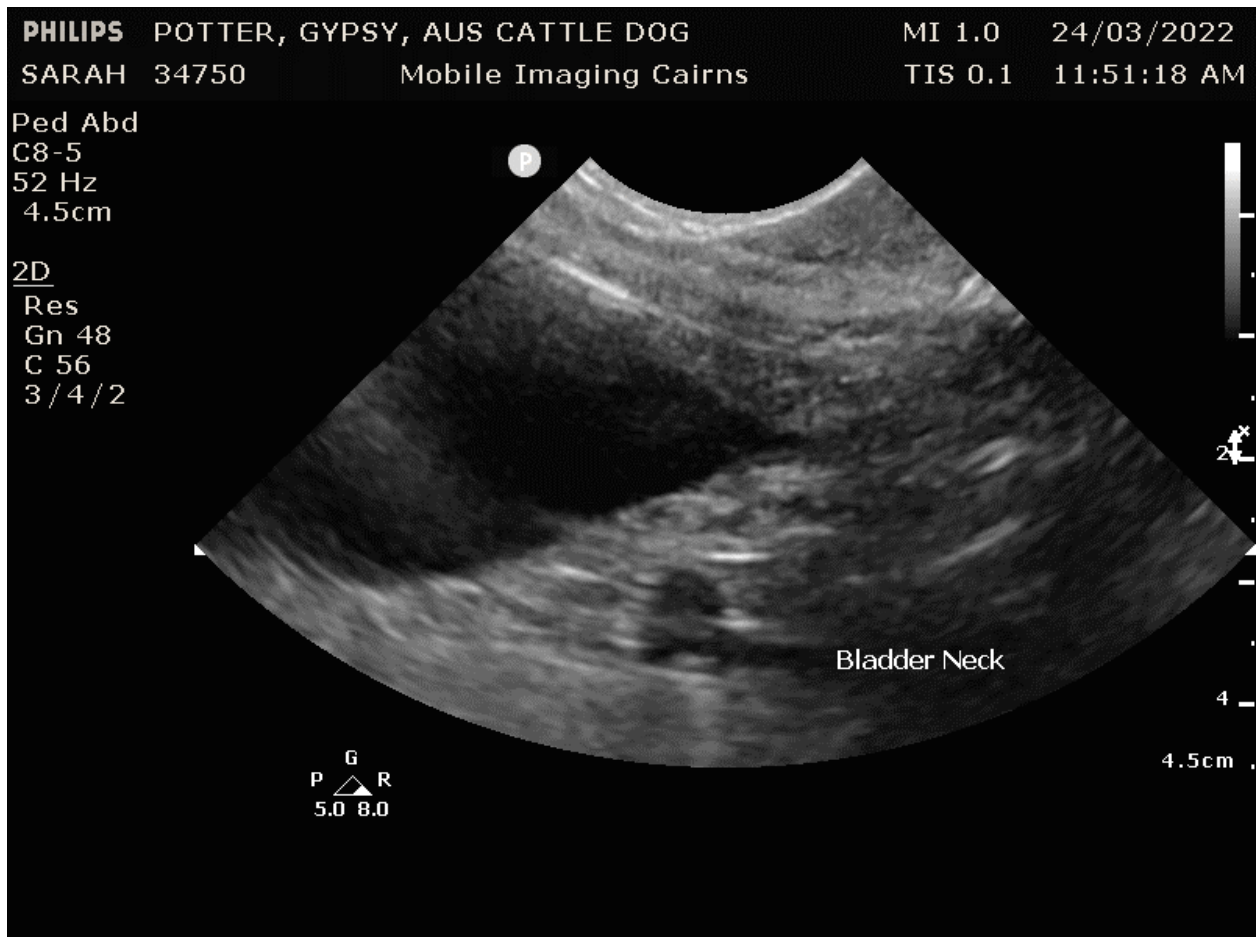32. Left kidney transverse view with measurement. The height is 2.91cm and the width is 3.51cm. The appearance is normal.



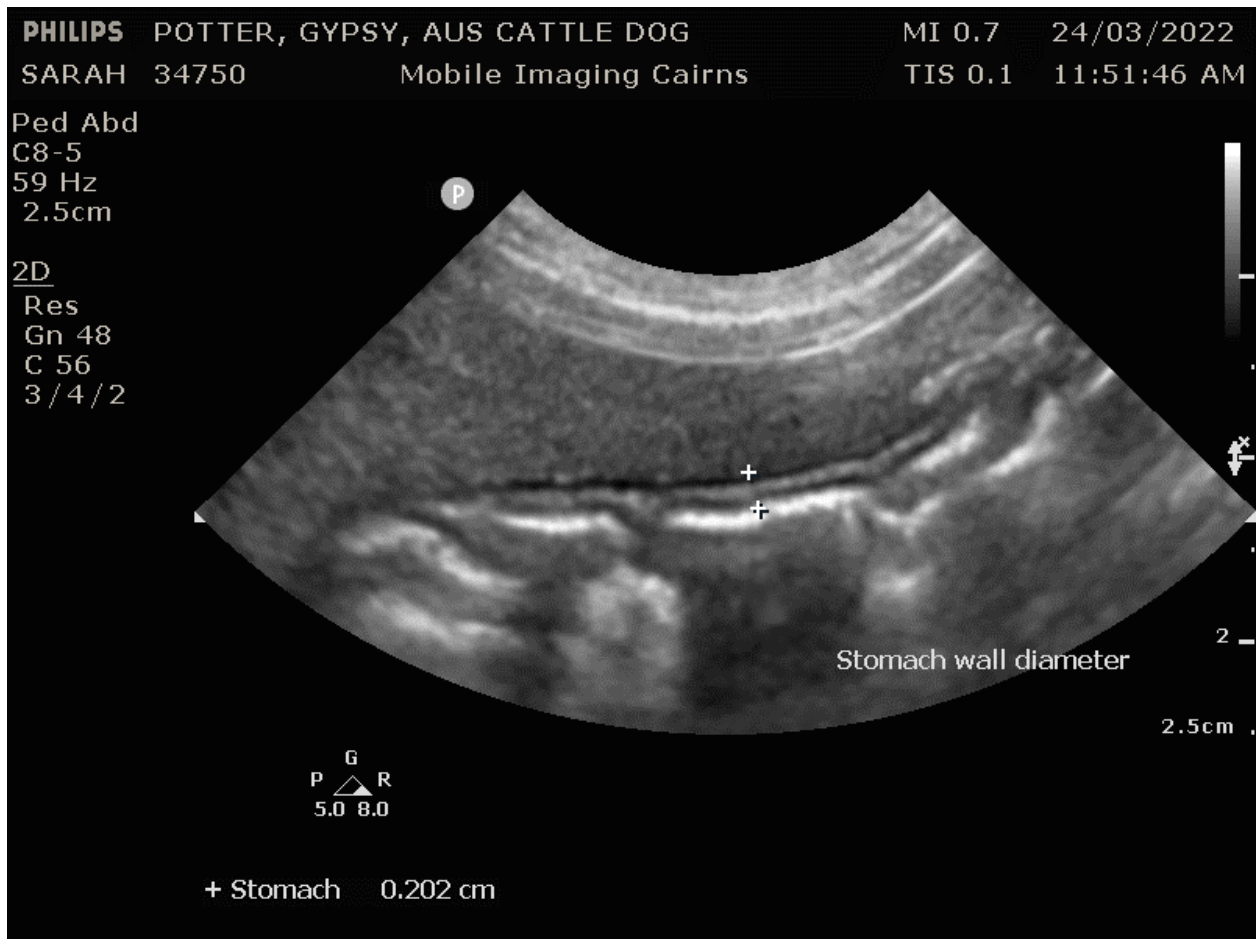
33. Urinary bladder sagittal view. The bladder is moderately full of anechoic urine. The bladder wall appears normal.



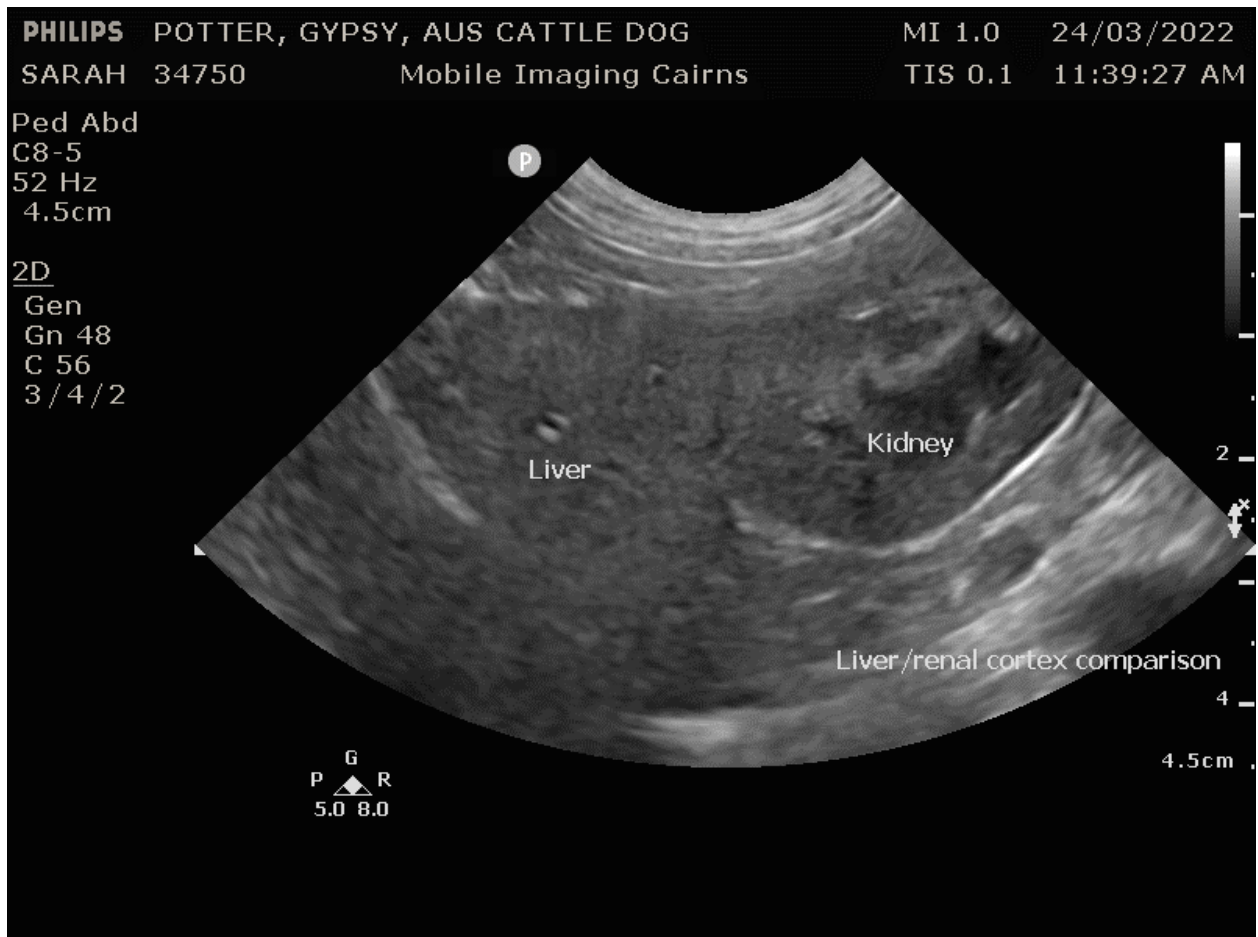34. Urinary bladder transverse view. The bladder is moderately full of anechoic urine. The bladder wall appears normal.



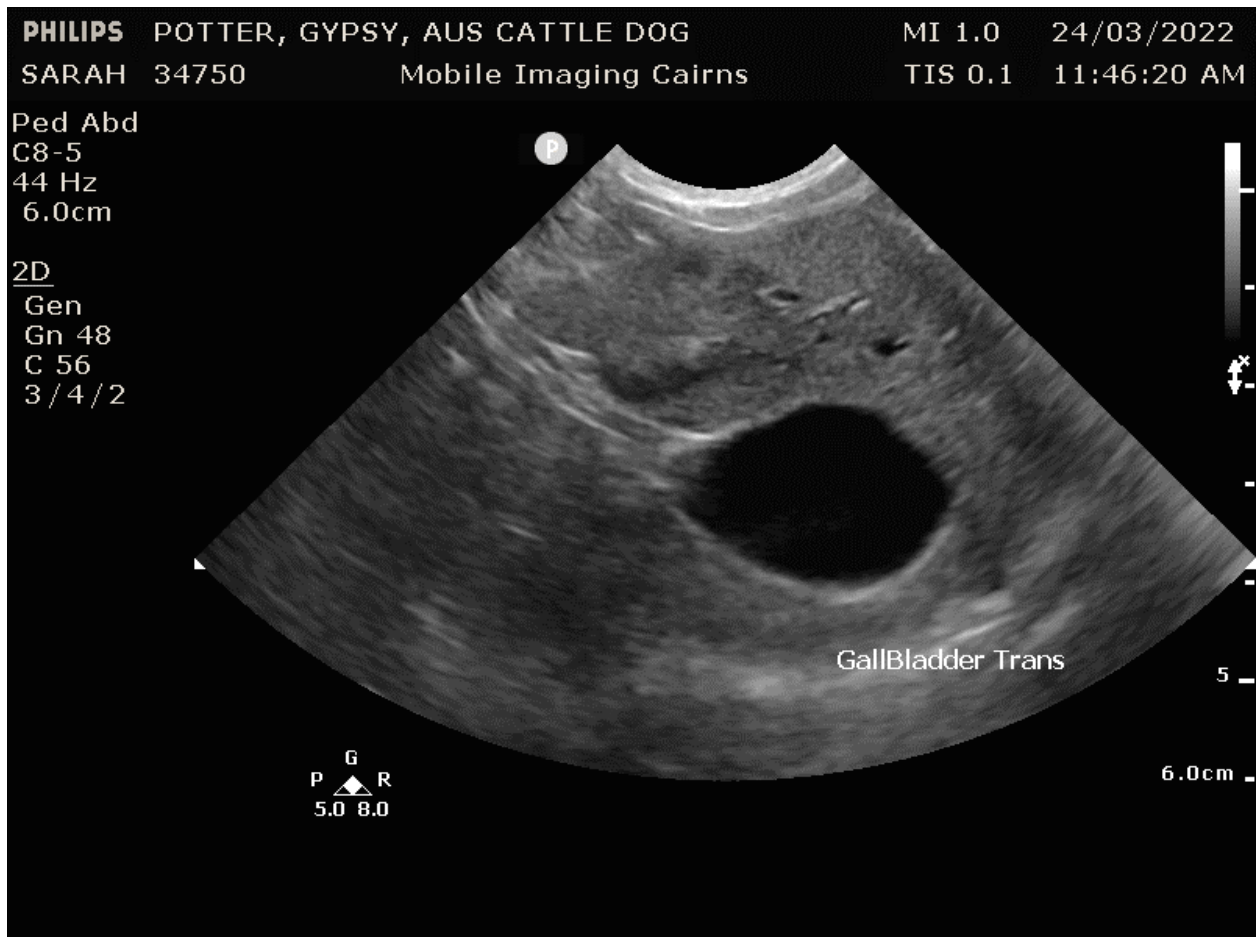
35. Bladder neck, sagittal view. The bladder neck appears normal.



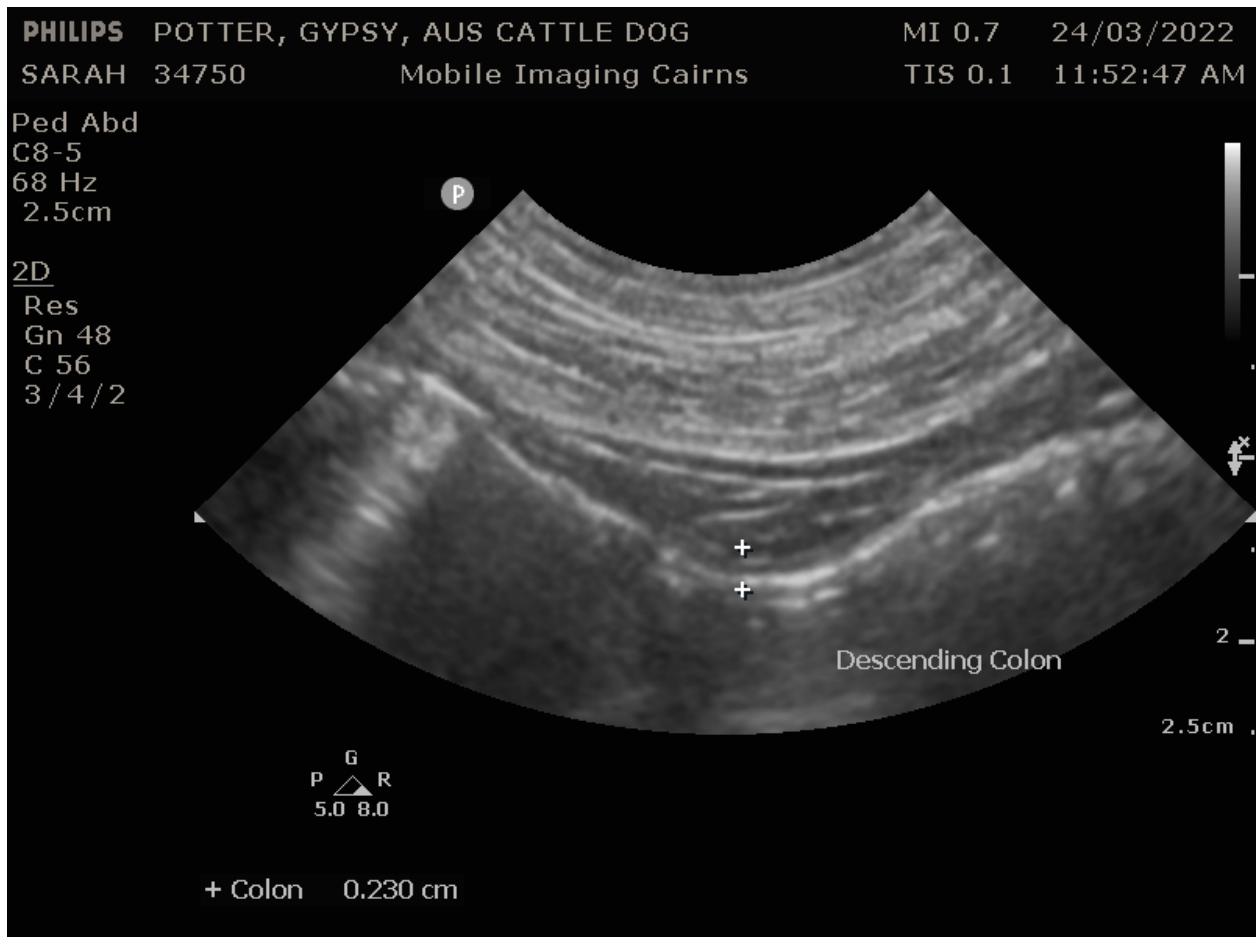
36. Stomach image with wall measurement. Wall layering appears normal. The wall measures 0.202cm in diameter, this is within normal limits².



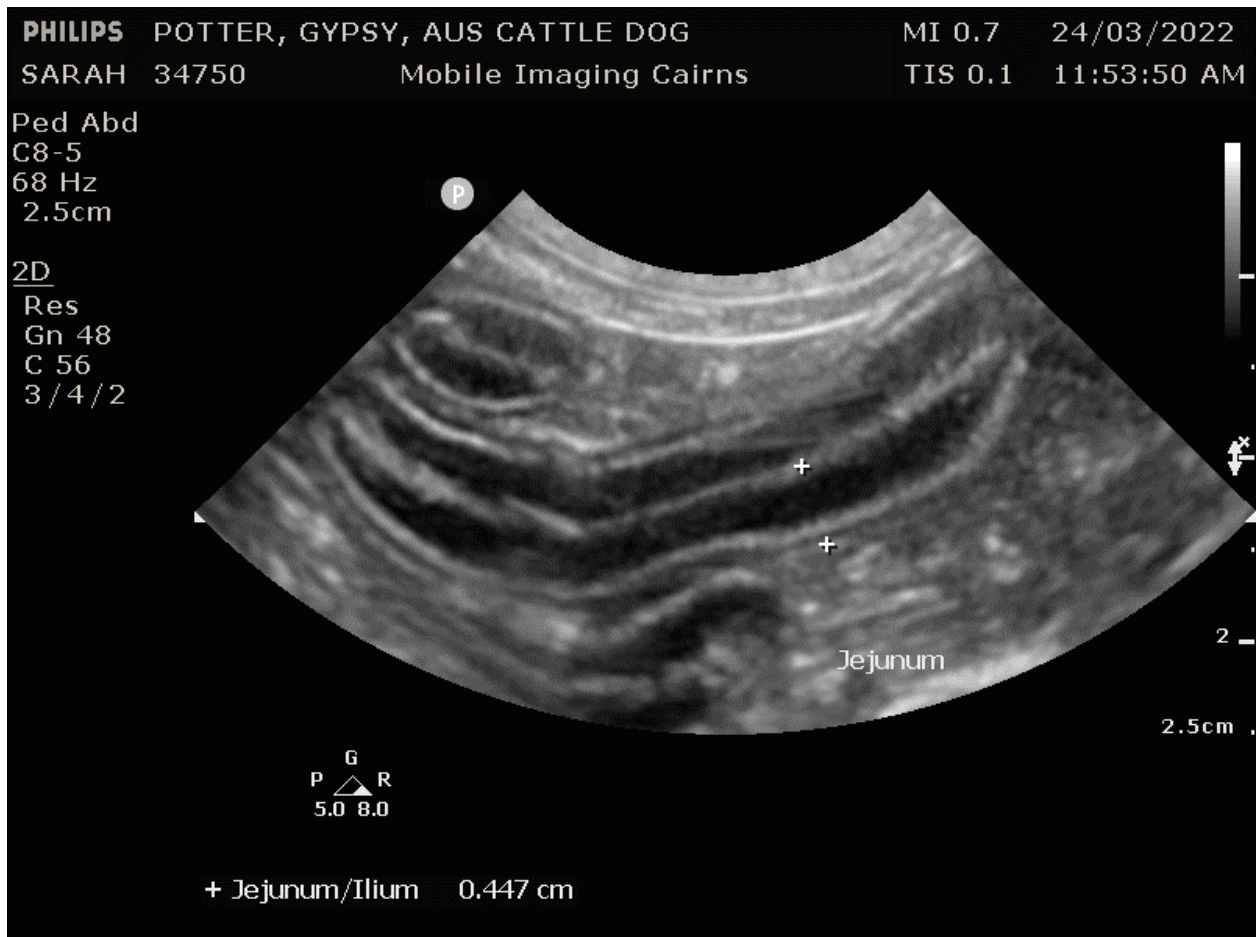37. Right liver/right kidney comparison sagittal view, as the dorsal view in 16 was sub optimal. At the same depth and gain settings the right renal cortex is isoechoic relative to the liver.



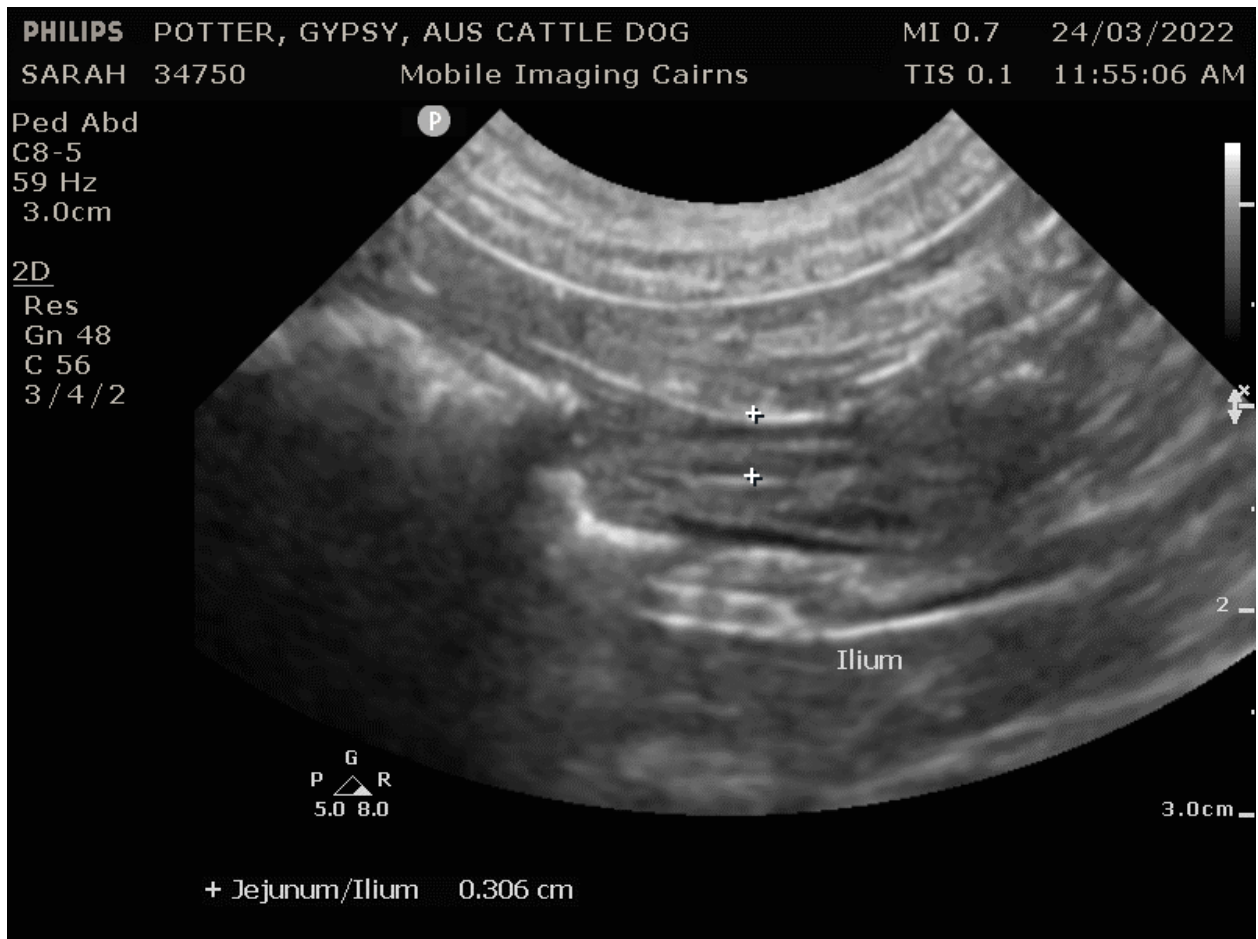
38. Transverse view of the gallbladder. The shape is normal. the walls are thin and smooth. There is some refractive shadowing and mild distal acoustic enhancement present.



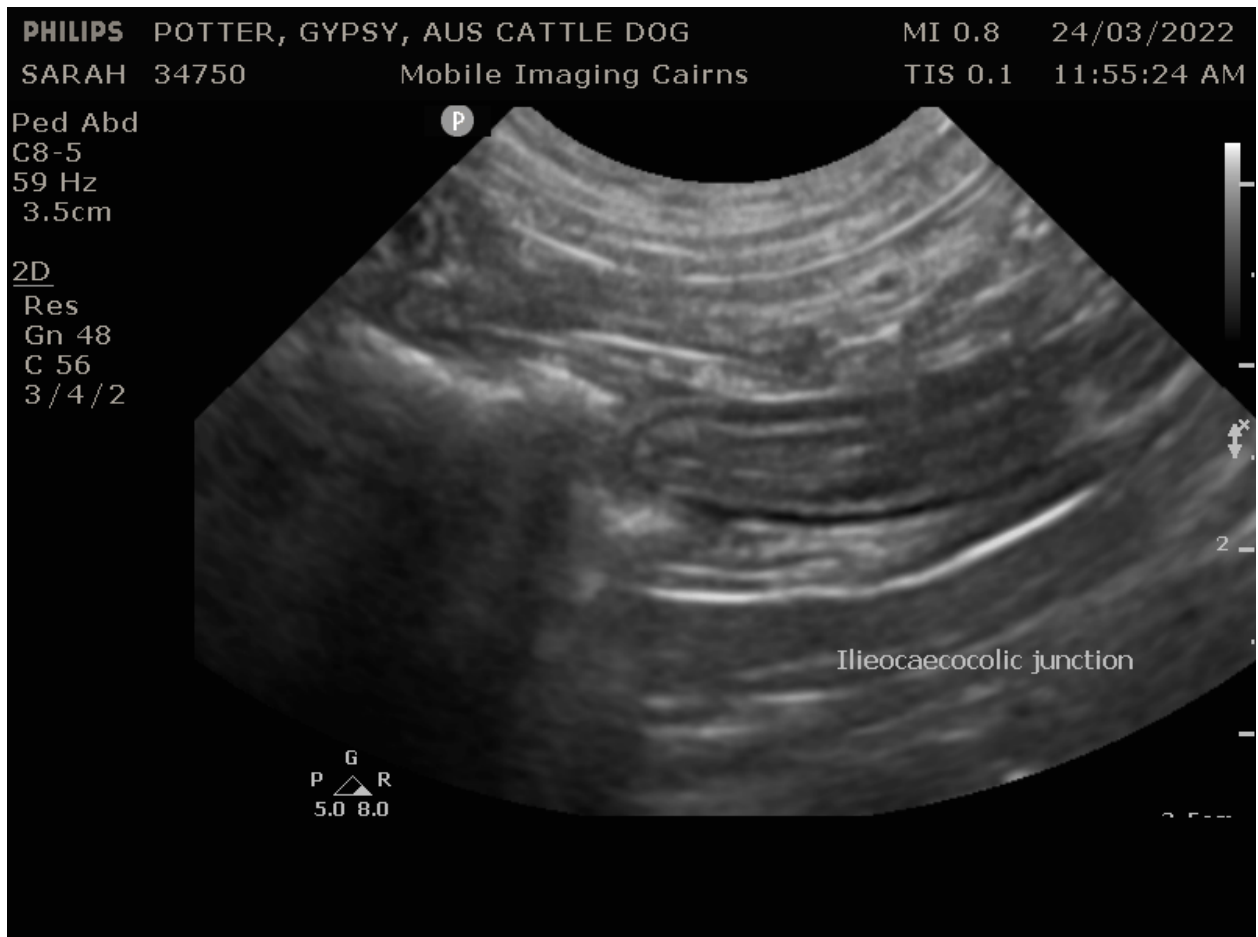
39. Longitudinal view of the descending colon. It measures 0.230cm in diameter which is within normal limits². It has smooth margins with normal gut layering present, there is a clean shadow caused by faecal contents.



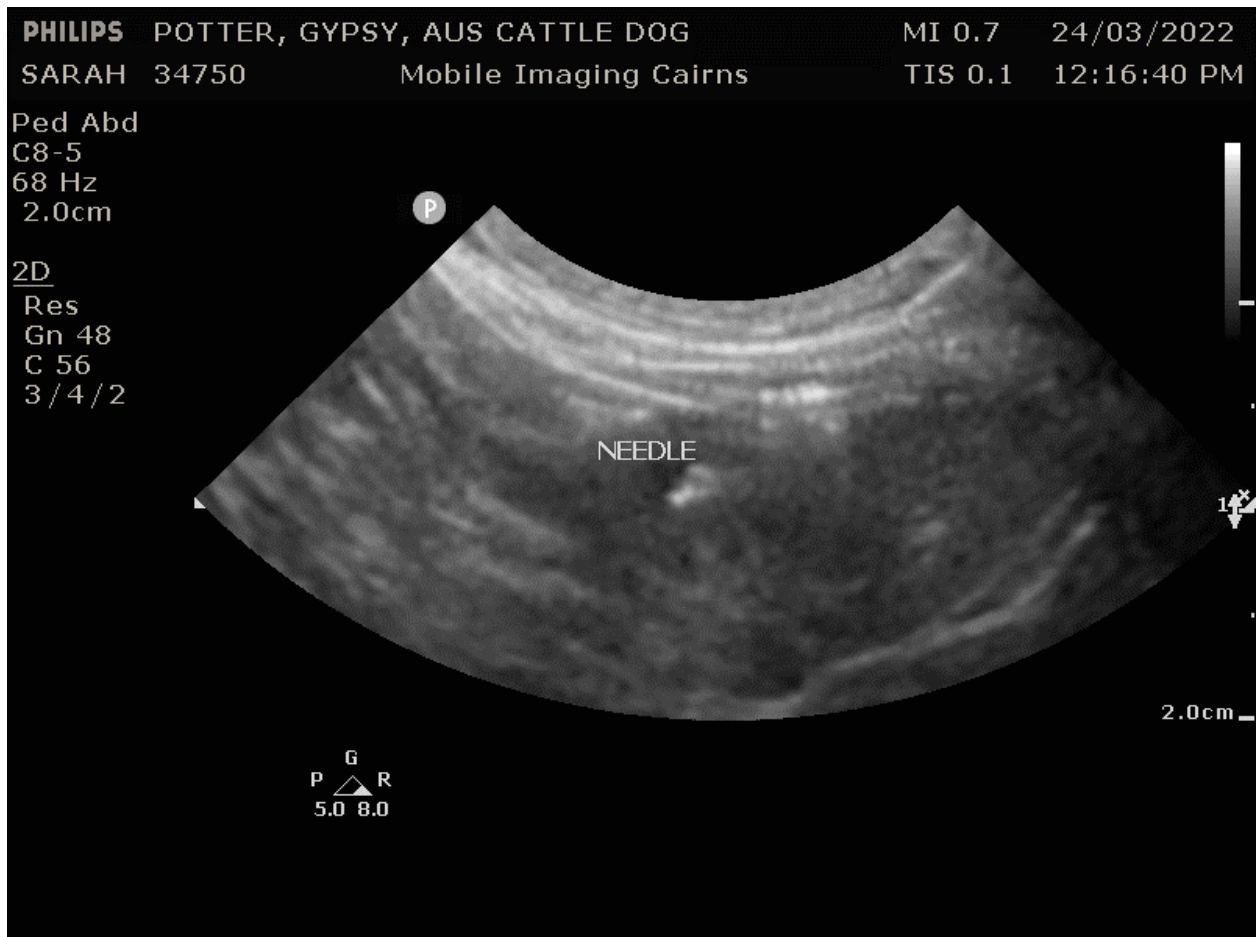
40. Longitudinal view of the jejunum, which measures 0.447cm in diameter. This is within the normal range.² It has smooth margins with normal gut layering present.



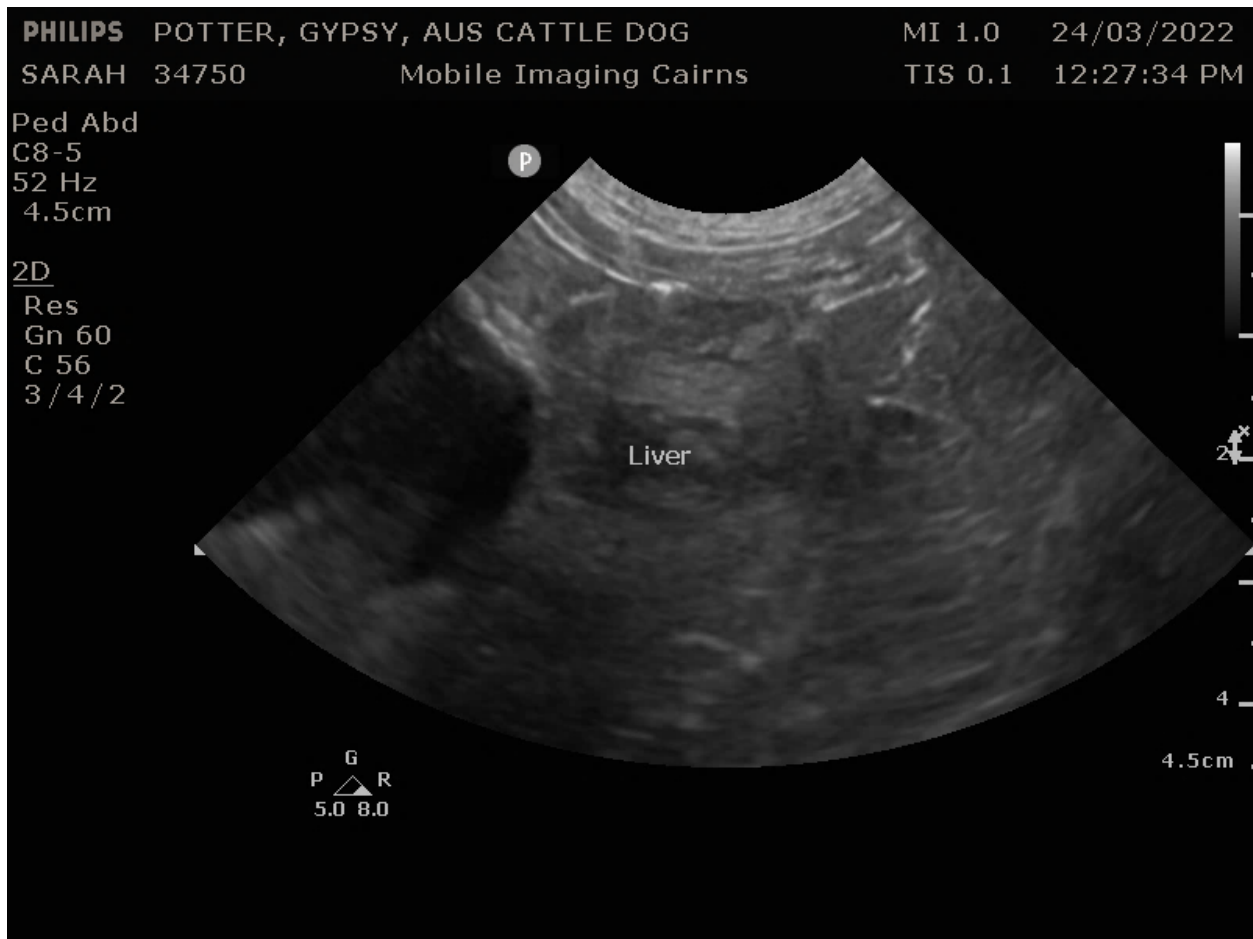41. Longitudinal view of the ileum, with measurements. It measures 0.306cm in diameter. It has smooth margins with normal gut layering present.



42. Longitudinal view of the ileocolic junction, this appears normal.



43. Fine needle aspiration showing needle placement within the liver mass.

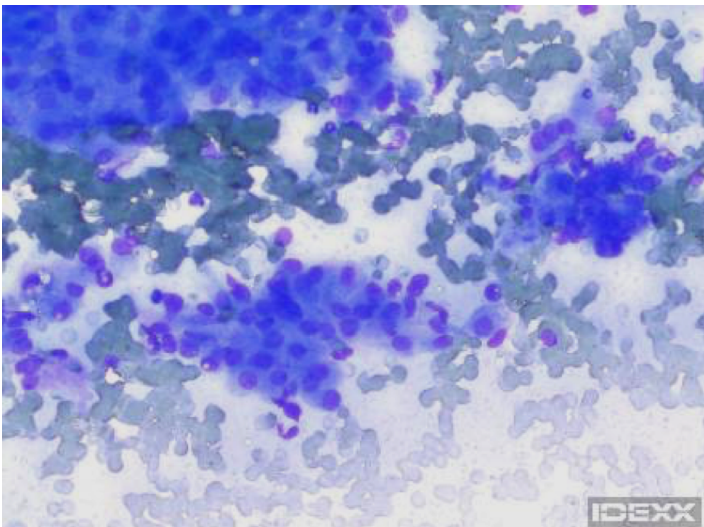
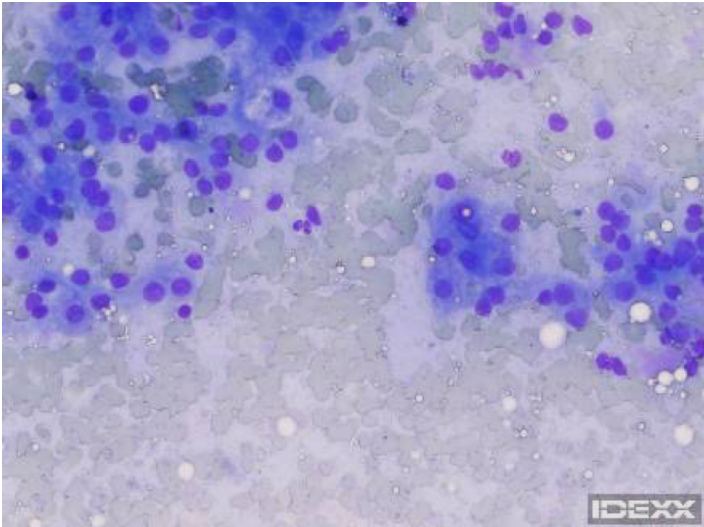
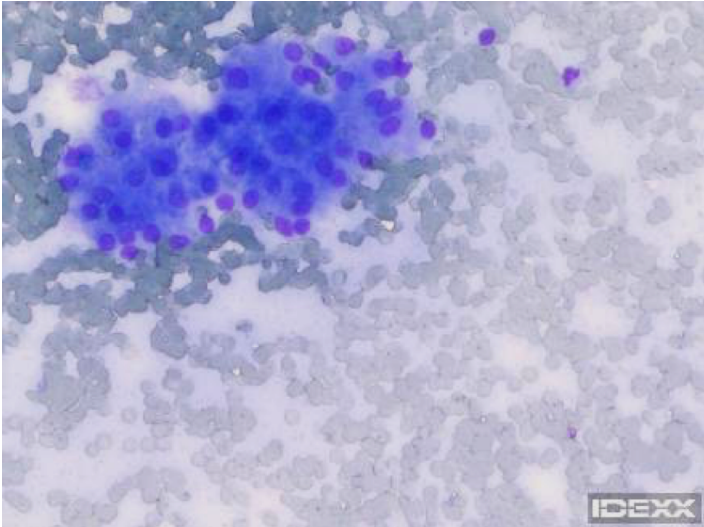


44. Examination of the liver ten minutes after aspiration to check for bleeding. There is no evidence of free fluid. Air filled tracks in the regions of the needle path can be seen in the near field as bright foci.

Interpretation summary

- There is a liver mass present. It is hypoechoic relative to its surrounds and heterogeneous in echotexture. Given that the dog is clinically well and eleven years old, the most likely diagnosis is nodular hyperplasia, however other conditions such as primary neoplasia, metastatic neoplasia, abscess or haematoma are also possible.
- Fine needle aspiration may provide a diagnosis, although the results may need to be interpreted with caution.
- There are multiple hypoechoic liver nodules present. These can be nodular hyperplasia, metastatic neoplasia, primary neoplasia, regenerative nodules, abscesses, haematomas or complex cysts.

Cytology report:



SPECIMEN SUBMITTED:

3 air dried slides from liver mass

CYTOLOGY FINDINGS: Samples consist of scant to moderate numbers of small and medium sized groups of hepatocytes and large numbers of red blood cells on an amphophilic background with low numbers of blood associated neutrophils and small lymphocytes. Hepatocytes have rounded cell margins, a moderate amount of amphophilic occasionally mildly non-lipid vacuolated cytoplasm and a single round nucleus with stippled chromatin and single nucleolus. Occasional binucleated cells are present. Pleomorphism is mild and mitotic figures are not seen.

INTERPRETATION: Mild hepatocellular pleomorphism with mild non-lipid vacuolar hepatopathy

COMMENTS: The hepatocytes may be reactive and seen with nodular hyperplasia, nodular regeneration, or a well differentiated hepatocellular neoplasm and differentiation between these processes is often not possible on cytology alone and requires histopathology (ideally a wedge biopsy or resection of the nodule if possible) to assess tissue architecture for the presence or absence of portal triads within the mass. Consider checking PT/aPTT prior to surgery and interpret with the peripheral blood results including indicators of hepatic function such as low albumin, low urea, low cholesterol, or low glucose.

Diagnosis

Unclassified liver mass with multiple smaller nodules present. The mass is likely to be nodular hyperplasia although neoplasia is possible.

The smaller nodules may be nodular hyperplasia, metastatic neoplasia, primary neoplasia, regenerative nodules, abscess, haematomas or complex cysts.

Treatment

A full oral examination and dental treatment was performed with removal of the oral mass. Gypsy recovered uneventfully.

Her owners declined further tests such as bile acid stimulation and histology of the oral mass based on financial concerns.

Needle biopsy of the liver and surgical liver biopsies were not performed due to the risk of complications and surgical recovery in a clinically well dog.

She was examined in June 2022 for routine vaccinations, her owner reported she continued to have no clinical signs.

Discussion

Ultrasound is of limited use in the investigation and diagnosis of liver disease in dogs. While it is considered sensitive for the detection of hepatic vascular abnormalities, it is unusual to diagnose other conditions with ultrasound alone. It is cheap, non-invasive, usually requires minimal sedation, and is readily assessable to most clinics, it is often more useful for evaluation of the liver than radiography, so it is advised if the limitations are clearly understood. Radiology, however, can prove easier for the diagnosis of abnormalities in hepatic size.

There are no reliable ultrasound features which may enable a tentative diagnosis of hepatic parenchymal disease.³ Studies have shown no sonographic findings reliably consistent with diffuse liver disease.^{4,5,8} The presence of abnormal hepatic lymph nodes or an abnormal spleen is believed to predict cytological evidence of hepatic neoplasia, however at least one study has found this not to be the case.⁴ Histological examination remains essential for the diagnosis of most canine hepatic disease.³

Ultrasound has been found to be insensitive for detecting hepatic lymphosarcoma,^{7,10} and diffuse mast cell infiltration.⁹ Normal liver appearance has been well reported in cases of infiltration with both neoplasms. It is advised to perform routine ultrasound guided aspiration of the liver in all canine mast cell¹¹ and lymphoma¹⁰ patients deemed to be at high risk for metastasis regardless of liver ultrasonographic appearance.

There have been studies into combining clinical laboratory and imaging data for the use in predicting the nature of focal liver lesions in dogs, in an attempt to increase the sensitivity of ultrasound.⁶ Greater lesion size and the presence of peritoneal fluid were the only variables that had a positive association with malignant liver disease.⁶ There is no way to determine if a focal lesion is benign or malignant by ultrasound.⁶

Ultrasound guided fine needle aspiration for cytological examination of the liver has serious limitations when used to identify the primary disease process in dogs with clinical evidence of liver disease.¹³ However, it is cheap and easy to perform, requires minimal equipment, it is often performed with minimal sedation and is considered safe.

Agreement between histology and cytology has been reported in approximately 30% of liver samples in the dog.¹³ Another study reported cytology agreeing completely or partially with biopsy specimens 80% of the time.¹⁴ There is controversy regarding its usefulness.

Vacuolar hepatopathy was the category with the highest percentage of agreement in one study and it was also found to be the prominent disease process.¹³ It was also the category that was most misdiagnosed via cytological examination in that same study.¹³ Another study found that disagreement was most common in cases of hepatitis in which inflammation was not seen in cytology specimens.¹⁴

One study found canine liver aspiration cytology is highly sensitive for the detection of suppurative and chronic active inflammation, and very insensitive for the detection of lymphocytic hepatitis.¹⁶ Cytologic diagnosis of inflammatory liver disease in aspiration smears is particularly troublesome, the liver is a highly vascular organ, and so all liver cytology specimens contain blood. The cytologist is left to determine whether inflammatory cells are the result of blood contamination or represent an inflammatory process.

Histology is considered more reliable than cytology.¹⁵ Ultrasound guided needle biopsy is considered safe and minimally invasive, although it does require anaesthetic. Ultrasound can be used to collect the sample from areas which are abnormal in appearance, even if they are deep within the liver.

Ultrasound guided needle biopsy does not always agree with the results taken at surgery or necropsy. Needle biopsy specimens from the dog need to be interpreted with caution.¹⁷ One study compared 18g spring triggered biopsy needles to wedge biopsy samples from the livers of dog and cats.¹⁷ It found morphological diagnosis assigned to needle biopsy specimens differed from diagnosis assigned in the paired wedge biopsy specimens. Needle biopsy agreed with wedge biopsies only 48% of the time.¹⁷ There is considerable variability in tissue involvement with certain disease processes. Ultrasonographic targeting can overlook areas having substantial histologic changes and obtaining few biopsy specimens from a single liver lobe cannot always represent the overall disease process.

Liver biopsy is an important step in the evaluation of a patient with hepatic disease and is required to formulate a diagnosis and direct therapy. Surgical biopsy is considered the best way to collect a sample.¹⁷ This may be collected during laparoscopy or via a laparotomy. Surgical exploration by laparotomy allows for gross examination of the liver including palpation and separation of the lobes, as well as collection of any other samples required from the abdomen. It is advised to collect the liver biopsies early in the laparotomy, because hepatocellular changes can result from prolonged anaesthesia, vascular changes during surgery and manipulation of the bowel.²¹ Surgery is invasive, requires anaesthesia and will have a variable recovery period. Because of this liver biopsy is rarely an indication for laparotomy in a dog with no clinical signs or changes in liver function.

An ideal liver biopsy should be of proper size and taken from a location that represents primary liver pathology.¹⁸ Liver biopsy only represents a small portion of the entire liver, so sampling error still needs to be considered. It is the only method of tissue collection to collect large enough samples for liver disease classification. This requires the examination of enough tissue to distinguish not only changes in the hepatobiliary and vascular structures but also the regional distribution of any lesion. The histologic appearance of the lesion and distribution may suggest chronicity, reversibility, and the type of insult.

Use of ultrasound contrast media have been studied, but these are not currently considered accurate enough to replace biopsy.³

CT has been explored for differentiating between hepatocellular carcinoma, adenoma, and nodular hyperplasia. It was found to be useful,¹² although it is not considered as accurate as histology. However, it is minimally invasive, although it does require anaesthesia and is not available to all clinics.

A standardisation committee was established to classify liver disease in dogs and cats.¹⁹

Vacuolar cytoplasmic changes were noted in Gypsy. The cytoplasmic accumulation of various substances leading to vacuole formation in hepatocytes can occur for a variety of reasons including nodular hyperplasia. The finding of vacuolar hepatopathy is consequently vague and often uninformative. Hepatic lipidosis and steroid induced vacuolar hepatopathies are among the most common diffuse parenchymal disorders in cats and dogs respectively.²

Nodular hyperplasia of hepatocytes is a common proliferative lesion in older dogs. One study showed that hyperplastic nodules were present in the liver of all of the dogs studied which were over fourteen years old.²⁰ It is of no clinical significance but should be distinguished from other disease. It is characterised by multiple distinct spherical and oval masses that are randomly distributed throughout the liver. Unaffected liver is usually normal. They can be difficult to distinguish from neoplasia by gross pathologic morphology.

The cause of benign nodular hyperplasia is unknown, changes in the perisinusoidal fat storing cells (Ito cells) have been observed in association with nodular hyperplasia.²⁰ It does not lead to liver dysfunction, and it does not progress to neoplasia. There are typically no clinical signs or physical changes, although hepatomegaly may be appreciated on clinical examination.

Biochemical changes include an increase in ALT, ALKP and sometimes AST. Liver function tests such as bile acid stimulation give normal results. Ultrasound appearance varies greatly from normal to masses of varying complexity and heterogeneity, including cavitation.

Diagnosis by cytology is unusual and it is considered unreliable, tissue biopsies are the only reliable way to diagnose the condition.

Histologically nodular hyperplasia is characterised by an expansile nodule of hepatocytes that retains normal lobular architecture and may compress adjacent normal liver tissue. There are more hepatocytes per unit area within nodules than in the adjacent parenchyma. Hepatocytes within the nodules are often vacuolated.²¹

Nodular hyperplasia does not appear to be associated with regenerative nodules, and it is unlikely that regenerative nodules are causing the changes seen on this study of Gypsy. They originate from the growth of surviving hepatocytes in a chronically changing liver. They also lack normal lobular architecture and there is typically only a single portal tract within the regenerative nodules.

Prognosis is excellent, and no treatment is required as this is a non-neoplastic condition. It does not affect quality of life or lead to morbidity or early mortality.

It can be difficult to distinguish hepatic nodular hyperplasia from hepatocellular adenoma or a well differentiated hepatocellular carcinoma.²² Primary hepatic tumours in dogs are less common than nodular hyperplasia, the prevalence is estimated to be around 0.6-1.5%.²³ The most common hepatic neoplasia is hepatocellular carcinoma, followed by bile duct carcinoma, carcinoid tumour and sarcoma. No predisposing factors are known and, in most cases, no additional primary liver pathology is present.²³

Hepatocellular adenomas are benign neoplasms of hepatocytes. They are easy to confuse histologically with hepatic nodular hyperplasia. They lack normal nodular architecture and are composed of well differentiated hepatocytes which tend to abut normal adjacent hepatocytes at right angles. Cystic areas containing haemorrhage or serum and foci of extramedullary haematopoiesis can be present.¹⁹

Hepatocellular carcinomas are malignant neoplasms composed of hepatocytes. They can be found in three forms, a mass form (a single large mass), a nodular form and a diffuse or infiltrative form, although the solitary form is the most common. These masses often develop in a single hepatic lobe.

On histology they can be trabecular, pseudoglandular and solid patterns. Mixtures of these patterns can be found within individual tumours.¹⁹

Treatment for a solitary hepatocellular carcinoma is surgical resection. In humans, near infrared fluorescence imaging using indocyanine green is used to identify masses intraoperatively, there have been studies investigating its use in dogs.²⁴

The prognosis for solitary masses of hepatocellular carcinoma is good when they are resected successfully.¹² Prognosis for nodular and diffuse hepatocellular carcinoma is poor.

Conclusion

Gypsy was an eleven-year-old female neutered cattle dog living in Cairns, Australia. She was diagnosed with dental disease and a full oral examination under general anaesthetic was planned. She was otherwise completely well; clinical examination was unremarkable. Preanaesthetic blood tests revealed a marked increase in ALKP and a mild increase in ALT. Ultrasonographic examination revealed a liver mass and multiple hypoechoic nodules, fine needle aspiration of the mass showed mild hepatocellular pleomorphism with mild non-lipid vacuolar hepatopathy. It was suggested that nodular hyperplasia, nodular regeneration or a well differentiated hepatocellular neoplasm were present. Collection of tissue for histology was not performed, and further tests for liver dysfunction (such as bile acid stimulation) were declined by the owner. Gypsy underwent her dental procedure without complications and continues to remain well with no clinical signs.

References

1. Mattoon JS, Nyland TG. 2015. *Small animal Diagnostic Ultrasound*. 3rd Edition. Elsevier publishing.
2. d'Anjou MA and Penninck D. Penninck D and d'Anjou MA (eds). *Atlas of small animal ultrasonography*. Iowa: John Wiley & Sons, 2015.
3. Warren-Smith CM, Andrew S, Mantis P, Lamb CR. Lack of associations between ultrasonographic appearance of parenchymal lesions of the canine liver and histological diagnosis. *J Small Anim Pract*. 2012 Mar;53(3):168-73.
4. Guillot M, Danjou MA, Alexander K, Bédard C, Desnoyers M, Beauregard G, Del Castillo JR. Can sonographic findings predict the results of liver aspirates in dogs with suspected liver disease? *Vet Radiol Ultrasound*. 2009 Sep-Oct;50(5):513-8.
5. Feeney DA, Anderson KL, Ziegler LE, Jessen CR, Daubs BM, Hardy RM. Statistical relevance of ultrasonographic criteria in the assessment of diffuse liver disease in dogs and cats. *Am J Vet Res*. 2008 Feb;69(2):212-21.
6. Murakami T, Feeney DA, Bahr KL. Analysis of clinical and ultrasonographic data by use of logistic regression models for prediction of malignant versus benign causes of ultrasonographically detected focal liver lesions in dogs. *Am J Vet Res*. 2012 Jun;73(6):821-9.
7. Lamb, C.R., Hartzband, L.E., Tidwell, A.S. and Pearson, S.H. (1991), ULTRASONOGRAPHIC FINDINGS IN HEPATIC AND SPLENIC LYMPHOSARCOMA IN DOGS AND CATS. *Veterinary Radiology*, 32: 117-120.
8. Vörös, K., Vrabély, T., Papp, L., Horváth, L. and Karsai, F. (1991), Correlation of ultrasonographic and patho-morphological findings in canine hepatic diseases. *Journal of Small Animal Practice*, 32: 627-634.
9. Sato AF, Solano M. Ultrasonographic findings in abdominal mast cell disease: a retrospective study of 19 patients. *Vet Radiol Ultrasound*. 2004 Jan-Feb;45(1):51-7.
10. Crabtree AC, Spangler E, Beard D, Smith A. Diagnostic accuracy of gray-scale ultrasonography for the detection of hepatic and splenic lymphoma in dogs. *Vet Radiol Ultrasound*. 2010 Nov-Dec;51(6):661-4.
11. Book AP, Fidel J, Wills T, Bryan J, Sellon R, Mattoon J. Correlation of ultrasound findings, liver and spleen cytology, and prognosis in the clinical staging of high metastatic risk canine mast cell tumors. *Vet Radiol Ultrasound*. 2011 Sep-Oct;52(5):548-54.
12. Fukushima, K., Kanemoto, H., Ohno, K., Takahashi, M., Nakashima, K., Fujino, Y., Uchida, K., Fujiwara, R., Nishimura, R. and Tsujimoto, H. (2012), CT CHARACTERISTICS OF PRIMARY HEPATIC MASS LESIONS IN DOGS. *Veterinary Radiology & Ultrasound*, 53: 252-257.

13. Wang KY, Panciera DL, Al-Rukibat RK, Radi ZA. Accuracy of ultrasound-guided fine-needle aspiration of the liver and cytologic findings in dogs and cats: 97 cases (1990-2000). *J Am Vet Med Assoc.* 2004 Jan 1;224(1):75-8.
14. Roth L. Comparison of liver cytology and biopsy diagnoses in dogs and cats: 56 cases. *Vet Clin Pathol.* 2001;30(1):35-38.
15. Huang SC, Liang JD, Hsu SJ, Hong TC, Yang HC, Kao JH. Direct comparison of biopsy techniques for hepatic malignancies. *Clin Mol Hepatol.* 2021 Apr;27(2):305-312.
16. Weiss DJ, Blauvelt M, Aird B. Cytologic evaluation of inflammation in canine liver aspirates. *Vet Clin Pathol.* 2001;30(4):193-196.
17. Cole TL, Center SA, Flood SN, Rowland PH, Valentine BA, Warner KL, Erb HN. Diagnostic comparison of needle and wedge biopsy specimens of the liver in dogs and cats. *J Am Vet Med Assoc.* 2002 May 15;220(10):1483-90.
18. Rothuizen J, Twedt DC. Liver biopsy techniques. *Vet Clin North Am Small Anim Pract.* 2009 May;39(3):469-80.
19. Cullen JM. Summary of the World Small Animal Veterinary Association standardization committee guide to classification of liver disease in dogs and cats. *Vet Clin North Am Small Anim Pract.* 2009 May;39(3):395-418.
20. Bergman JR. Nodular hyperplasia in the liver of the dog: an association with changes in the Ito cell population. *Vet Pathol.* 1985 Sep;22(5):427-38.
21. Fabry A, Benjamin SA, Angleton GM. Nodular hyperplasia of the liver in the beagle dog. *Vet Pathol.* 1982 Mar;19(2):109-19.
22. Stowater, J.L., Lamb, C.R. and Schelling, S.H. (1990), ULTRASONOGRAPHIC FEATURES OF CANINE HEPATIC NODULAR HYPERPLASIA. *Veterinary Radiology*, 31: 268-272.
23. van Sprundel RG, van den Ingh TS, Guscetti F, Kershaw O, Kanemoto H, van Gils HM, Rothuizen J, Roskams T, Spee B. Classification of primary hepatic tumours in the dog. *Vet J.* 2013 Sep;197(3):596-606.
24. Kosaka N, Ogawa M, Choyke PL, Kobayashi H. Clinical implications of near-infrared fluorescence imaging in cancer. *Future Oncol.* 2009 Nov;5(9):1501-11.